

3. Shively JE, Beatty JD. CEA-related antigens: molecular biology and clinical significance. *Crit Rev Oncol Hematol* 1985; 2: 355–399.
4. Phay JE, Shah MH. Targeting RET receptor tyrosine kinase activation in cancer. *Clin Cancer Res* 2010; 16: 5936–5941.
5. Therasse P, Arbuck SG, Eisenhauer EA et al. New guidelines to evaluate the response to treatment in solid tumors. European Organization for Research and Treatment of Cancer, National Cancer Institute of the United States, National Cancer Institute of Canada. *J Natl Cancer Inst* 2000; 92: 205–216.
6. Kaplan EL, Meier P. Nonparametric estimation from incomplete observations. *J Am Stat Assn* 1958; 53: 457–481.
7. Cohen R, Campos JM, Salaun C et al. Preoperative calcitonin levels are predictive of tumor size and postoperative calcitonin normalization in medullary thyroid carcinoma. Groupe d'Etudes des Tumeurs a Calcitonine (GETC). *J Clin Endocrinol Metab* 2000; 85: 919–922.
8. Hong DS, Sebti SM, Newman RA et al. Phase I trial of a combination of the multikinase inhibitor sorafenib and the farnesyltransferase inhibitor tipifarnib in advanced malignancies. *Clin Cancer Res* 2009; 15: 7061–7068.
9. Kurzrock R, Sherman SI, Ball DW et al. Activity of XL184 (Cabozantinib), an oral tyrosine kinase inhibitor, in patients with medullary thyroid cancer. *J Clin Oncol* 2011; 29: 2660–2666.
10. Akeno-Stuart N, Croyle M, Knauf JA et al. The RET kinase inhibitor NVP-AST487 blocks growth and calcitonin gene expression through distinct mechanisms in medullary thyroid cancer cells. *Cancer Res* 2007; 67: 6956–6964.
11. Busnardo B, Girelli ME, Simioni N et al. Nonparallel patterns of calcitonin and carcinoembryonic antigen levels in the follow-up of medullary thyroid carcinoma. *Cancer* 1984; 53: 278–285.
12. Ito K, Hibi K, Ando H et al. Usefulness of analytical CEA doubling time and half-life time for overlooked synchronous metastases in colorectal carcinoma. *Jpn J Clin Oncol* 2002; 32: 54–58.
13. Fugazzola L, Pinchera A, Luchetti F et al. Disappearance rate of serum calcitonin after total thyroidectomy for medullary thyroid carcinoma. *Int J Biol Markers* 1994; 9: 21–24.
14. Benjamin RS, Choi H, Macapinlac HA et al. We should desist using RECIST, at least in GIST. *J Clin Oncol* 2007; 25: 1760–1764.
15. Choi H, Charnsangavej C, Faria SC et al. Correlation of computed tomography and positron emission tomography in patients with metastatic gastrointestinal stromal tumor treated at a single institution with imatinib mesylate: proposal of new computed tomography response criteria. *J Clin Oncol* 2007; 25: 1753–1759.
16. Wolchok JD, Hoos A, O'Day S et al. Guidelines for the evaluation of immune therapy activity in solid tumors: immune-related response criteria. *Clin Cancer Res* 2009; 15: 7412–7420.
17. Schlumberger M, Carlomagno F, Baudin E et al. New therapeutic approaches to treat medullary thyroid carcinoma. *Nat Clin Pract Endocrinol Metab* 2008; 4: 22–32.
18. Mannini D, Maver P, Aiello E et al. Spontaneous circadian fluctuations of prostate specific antigen and prostatic acid phosphatase serum activities in patients with prostatic cancer. *Urol Res* 1988; 16: 9–12.

Annals of Oncology 24: 2261–2266, 2013

doi:10.1093/annonc/mdt180

Published online 23 May 2013

Tumour response and safety of cetuximab in a window pre-operative study in patients with squamous cell carcinoma of the head and neck

S. Schmitz^{1,2}, M. Hamoir², H. Reyckler³, M. Magremanne³, B. Weynand⁴, R. Lhomme⁵, F.-X. Hanin⁵, T. Duprez⁶, N. Michoux⁶, D. Rommel⁶, M. Lonneux⁵, N. Cappoen¹, A. Gillain¹ & J.-P. Machiels^{1,2*}

¹Cancer Center, Department of Medical Oncology, Cliniques universitaires Saint-Luc and Institut de Recherche Clinique et Expérimentale (Pole MIRO), Université catholique de Louvain, Brussels; ²Department of Head and Neck Surgery, Cliniques universitaires Saint-Luc, Université catholique de Louvain, Brussels; ³Department of Oral and Maxillofacial Surgery, Cliniques universitaires Saint-Luc, Université catholique de Louvain, Brussels; ⁴Department of Anatomopathology, Université catholique de Louvain, Cliniques universitaires Saint-Luc and CHU Mont-Godinne, Brussels, Yvoir; Departments of ⁵Nuclear Medicine; ⁶Medical Imaging and Radiology, Cliniques universitaires Saint-Luc, Université catholique de Louvain, Brussels, Belgium

Received 21 November 2012; revised 21 March 2013; accepted 3 April 2013

Background: To investigate the safety and activity of cetuximab in the pre-operative treatment of squamous cell carcinoma of the head and neck (SCCHN).

Patients and methods: Cetuximab was administered for 2 weeks before surgery to 33 treatment-naïve patients selected for primary surgical treatment. Tumour biopsies, 2-[fluorine-18]-fluoro-2-deoxy-D-glucose positron emission tomography (¹⁸FDG-PET) and imaging were carried out at baseline and before surgery. The primary aim of the study was safety and the secondary aims included metabolic, radiological and pathological tumour response. Five untreated patients were included as controls.

*Correspondence to: Dr J.-P. Machiels, Service d'oncologie médicale, Cliniques universitaires Saint-Luc, Université catholique de Louvain, 10 Avenue Hippocrate, 1200 Brussels, Belgium. Tel: +32-2-764-54-57; Fax: +32-2-764-54-28; E-mail: jean-pascal.machiels@uclouvain.be

Results: Cetuximab given 24 h before surgery was safe. Ninety percent of patients had ^{18}F FDG-PET partial response (EORTC guideline) in the cetuximab group versus 0% in the control group. Delta maximal standardized uptake values ($\Delta\text{SUV}_{\text{max}}$) were correlated with tumour cellularity on the surgical specimens ($P < 0.0001$). For patients with $\Delta\text{SUV}_{\text{max}}$ less than -25% or less than -50% , Ki67 was significantly decreased by cetuximab ($P = 0.01$ and 0.003). Cetuximab induced down-regulation of pEGFR ($P = 0.0004$) and pERK ($P = 0.003$).

Conclusions: Short-course pre-operative administration of cetuximab is safe and shows a high rate of ^{18}F FDG-PET response. ^{18}F FDG-PET response was correlated with residual tumour cellularity suggesting that ^{18}F FDG-PET deserves further investigation as a potential early marker of cetuximab activity in SCCHN.

Key words: cetuximab, head and neck cancer, targeted therapy

introduction

Cetuximab, an IgG1 monoclonal antibody (mAb) that targets the epidermal growth factor receptor improves (EGFR) improves survival (OS) in patients with squamous cell carcinoma of the head and neck (SCCHN) patients when given either in combination with radiation therapy as curative treatment or with chemotherapy in the palliative setting [1, 2]. However, only a minority of patients benefit from anti-EGFR mAbs [2]. Better understanding of involved molecular mechanisms is needed to optimize treatment with anti-EGFR mAbs.

One way to study the molecular mechanisms and activity of a particularly treatment is to perform trials that collect tumour biopsies pre- and post-treatment. However, targeted agents are often investigated in unselected end-stage cancer patients, the majority of whom will have already received radiation and/or chemotherapy and/or surgery. This leads to multifactorial resistance with modifications in tumour composition, peritumoral stroma and vascularization, making these patients less likely to respond to new agents. Additionally, there are some ethical considerations in obtaining repetitive tumour biopsies in patients with palliative disease. Evaluation of compounds in this pre-operative window setting in previously untreated patients could maximize the probability of observing tumour response.

In this study, we investigated the safety of cetuximab, together with molecular and imaging responses to the drug, when administered pre-operatively for the treatment of SCCHN.

patients and methods

inclusion and exclusion criteria

Eligible patients were required to have an untreated histologically proven T1-T4 SCC of the oral cavity, oropharynx, hypopharynx or larynx and ECOG performance status 0–1. Patients had to be selected for primary surgical treatment with curative intent following multidisciplinary discussion.

The clinical and translational parts of the study were approved by the Independent Ethics Committee and the Belgian Health Authorities and conducted in accordance with the Declaration of Helsinki (October 2000). Written informed consent was obtained for each patient.

study end points and outcome

The primary end point was the safety of pre-operative administration of cetuximab. Secondary end points included the activity of cetuximab

according to 2-[fluorine-18]-fluoro-2-deoxy-D-glucose positron emission tomography (^{18}F FDG-PET) and translational research. Magnetic resonance imaging (MRI) and/or computed tomography (CT) scan response were considered as exploratory end points and analysed only in patients with measurable disease according to RECIST criteria.

study design

This study was a single-institution, open-label non-comparative study, divided into two parts. The main objective of the first part was to determine the safe minimum delay between pre-operative cetuximab infusion and surgery. Tumour biopsies were collected and imaging studies were carried out to create a baseline learning curve for the surgical and imaging teams. The second part of the trial consisted of an expansion cohort to confirm the safety of the minimum delay identified in the first part and to investigate the metabolic activity of cetuximab.

safety part of the study

Patients received intravenous cetuximab at a loading dose of 400 mg/m^2 on first administration followed by $250 \text{ mg/m}^2/\text{week}$ for the second and third infusions, if applicable. The safe minimum delay between pre-operative cetuximab infusion and surgery was the dose delay below the one that gave ≥ 2 limiting toxic effects. This was determined by the independent safety committee after careful review of the patient files. Limiting toxic effect was defined as any life-threatening (grade 4) or unexpected surgical toxic effect including, but not limited to, pre- or post-operative bleeding and delayed wound healing. Five delay schedules were pre-defined between the last administration of cetuximab and surgery: delay schedule I: 10–12 days delay between the second cetuximab infusion and surgery (two infusions of cetuximab); delay schedule II: 6–8 days delay between the second cetuximab infusion and surgery (two infusions of cetuximab); delay schedule III: 3–4 days delay between the second cetuximab infusion and surgery (two infusions of cetuximab); delay schedule IV: 3–4 days delay between the third cetuximab infusion and surgery (three infusions of cetuximab); delay schedule V: 24-h delay between the third cetuximab dose and surgery (three infusions of cetuximab). The cohort size was three patients per delay schedule, extended to six patients if one limiting toxic effect was observed in the first three patients. Next dose delay was investigated if < 1 of 3 patients or < 2 of 6 patients in the previous dose delay had limiting toxic effects. If two of three or six patients had limiting toxic effects, the study was stopped.

Adverse events were collected and graded using the National Cancer Institute Common Terminology Criteria for Adverse Events, v 3.0.

expansion part of the study

All patients were treated with a loading dose of 400 mg/m^2 on day -15 before surgery followed by 250 mg/m^2 on days -8 and -1 before surgery (day 0).

To investigate the pathological and imaging responses, it was pre-planned to combine the patients treated with delay schedule V, if this schedule was found feasible, with the patients in this expansion cohort.

control group

It was pre-planned to recruit five additional patients as controls. These patients were not treated with cetuximab but underwent ^{18}F FDG-PET and tumour biopsies at the same time points as the patients in the expansion cohort.

pre-treatment evaluation and study assessments

Baseline assessments (before day -15) included staging upper airway panendoscopy under general anaesthesia with tumour biopsies and cervical imaging by ^{18}F FDG-PET with contrast-enhanced CT. A second ^{18}F FDG-PET with contrast-enhanced CT scan (day -1) was carried out strictly 2 h after the last cetuximab infusion for all patients. As interpretation of CT imaging was impaired by dental artefacts, the protocol was amended to perform pre- and post-treatment MRI for the last seven patients. Delta maximal standardized uptake values ($\Delta\text{SUV}_{\text{max}}$) was the relative percentage of SUV_{max} modification between two ^{18}F FDG-PET studies: $((\text{SUV}_{\text{max}} \text{ post-treatment PET} - \text{SUV}_{\text{max}} \text{ baseline PET}) / \text{SUV}_{\text{max}} \text{ baseline PET}) \times 100$. Response was evaluated based on the EORTC criteria for solid tumour evaluation with ^{18}F FDG-PET [3].

Residual tumour cellularity was determined on haematoxylin and eosin-stained slides including the whole tumour. Tumour cellularity (expressed as a percentage) was the surface occupied by tumour cells divided by the surface of the whole tumour.

Additional technical guidelines regarding imaging and immunohistochemistry (IHC) are provided in supplementary data S1 and S2, available at *Annals of Oncology* online.

statistical methods

The number of patients in the safety part of this study was based on the safety data according to the independent safety committee. The number of patients required in the expansion part was based on a hypothesis regarding cetuximab activity evaluated by ^{18}F FDG-PET ($P_0 = 0.15$, $P_1 = 0.40$, $\alpha = 0.10$ and $\beta = 0.10$; Fleming's one stage) [4]. Based on this test, 19 ^{18}F FDG-PET evaluable patients treated with the delay schedule selected in the first part of the study were required. The study was closed when 19 patients with evaluable ^{18}F FDG-PET were included in the expansion part.

No statistical comparisons were planned and carried out between the control and the cetuximab groups.

Differences in protein expression (IHC) were determined by a paired Wilcoxon signed-rank test. A non-parametric correlation test (Spearman test) was carried out to correlate tumour cellularity and metabolic modifications. These pathological analyses were carried out only in patients included in the expansion part of the study.

results

patient characteristics

Thirty-three patients were treated with pre-operative cetuximab between August 2008 and February 2011. One patient had to be excluded because pathological review of the surgical specimen revealed melanoma, despite the initial biopsies supporting a diagnosis of SCC (supplementary data S3, available at *Annals of Oncology* online).

safe minimum delay between pre-operative cetuximab infusion and surgery

No limiting toxic effects were observed during the first four dose-delay schedules. A patient on schedule V presented with grade 4 acute bleeding 2 h after surgery. Additional analyses did not diagnose a major coagulation disorder (i.e. haemophilia or Von Willebrand disease) but a careful review of her medical history revealed that she had experienced a similar acute post-operative bleeding complication 10 years before. No surgical complications were observed in the three additional patients recruited to dose-delay schedule V. The independent safety committee decided that the trial could therefore proceed to the expansion part.

toxic effect

In the expansion cohort, no additional limiting toxic effects were observed. Adverse events for the whole group are shown in Table 1. The main grade 3–4 toxic effect was cutaneous rash ($n = 3$, 9%). No cetuximab dose reductions were necessary.

^{18}F FDG-PET activity

Eighteen of 19 patients in the cetuximab group (expansion cohort) had a partial response (PR) according to the ^{18}F FDG-PET EORTC guidelines versus 0% in the control group. More details regarding ^{18}F FDG-PET results are summarized in Table 2.

Table 1. Acute adverse events according to NCI-CTC (version 3) criteria

$n = 33^a$	Grade 1–2	Grade 3–4
Dermatologic (Rash)	29 (66%)	3 (9%)
Diarrhea	1 (3%)	0%
Hypocalcaemia	12 (37.5%)	0%
Hypomagnesium	2 (6%)	0%
Hypophosphorus	5 (16%)	0%
Stomatitis	2 (6%)	0%
Nail changes	1 (3%)	0%
Post-operative bleeding	0	1 (3%)

^aOne patient with a final diagnosis of mucosal melanoma.

Table 2. $\Delta\text{SUV}_{\text{max}}$ between the baseline and post-treatment ^{18}F FDG-PET

	Safety part $n = 12$ (32%)	Expansion part $n = 20$ (54%)	Control $n = 5$ (14%)
Number of patients evaluable by ^{18}F FDG-PET	10	19	5
$\Delta\text{SUV}_{\text{max}} > +25\%$	0	0	1 (20%)
$\Delta\text{SUV}_{\text{max}}$ between $+25\%$ and -25%	2 (20%)	1 (5%)	4 (80%)
$\Delta\text{SUV}_{\text{max}}$ between -25% and -50%	2 (20%)	8 (42%)	0
$\Delta\text{SUV}_{\text{max}}$ between -50% and -75%	6 (60%)	8 (42%)	0
$\Delta\text{SUV}_{\text{max}} < -75\%$	0	2 (11%)	0

CT-scan and MRI

Fourteen of the 20 patients treated with cetuximab infused 24 h before surgery (expansion cohort) had measurable lesions on CT or MRI according to RECIST. For eight patients, the largest diameters of the tumour decreased (−8% to −30%), whereas six patients had either no modification of their largest diameter ($n = 2$) or a small increase (+2% to −6%) ($n = 4$).

clinical response

Tumour diameter and mucosal aspects were measured and evaluated during the baseline staging endoscopy and, again after treatment, during surgery. Although the majority of patients (28/32) had no significant macroscopic volume modifications of the tumour, we observed superficial modifications in all tumours that were less ulcerated and covered by a fibrotic membrane (supplementary data S4, available at *Annals of Oncology* online). Four patients had macroscopic tumour reduction with a $\Delta\text{SUV}_{\text{max}} < -60\%$.

histology

A first analysis was carried out to evaluate tumour cellularity in the resected specimens of control patients ($n = 5$) and those with an evaluable ^{18}F FDG-PET who received cetuximab 24 h before surgery. All patients in the control group had tumour cellularity superior to >60%. Fifteen patients in the cetuximab group had <50% of residual tumour cellularity with five of them <25%. We found a significant correlation between $\Delta\text{SUV}_{\text{max}}$ and residual tumour cellularity measured on the resected specimens ($r = 0.84$, $P < 0.0001$) (Figure 1).

Paired biopsies were obtained for the 19 patients treated with cetuximab infused 24 h before surgery and for the 5 patients in the control group. We compared pre- and post-treatment samples and observed decreased expression of pEGFR ($P = 0.0004$) and pERK ($P = 0.003$) but not of pAKT/AKT ($P = 0.2/P = 0.6$) (supplementary data S5, available at *Annals of Oncology* online) and Ki67. Baseline levels of pEGFR, pERK and pAKT, as well as their modifications under treatment, were not correlated with $\Delta\text{SUV}_{\text{max}}$. For the whole population, there was a trend towards down-regulation of Ki67 ($P = 0.04$). For patients with $\Delta\text{SUV}_{\text{max}}$ less than −25% or less than −50%, Ki67 was more significantly decreased ($P = 0.01$ and $P = 0.003$) (Figure 2).

In the five control patients, we did not observe any significant modifications to these same analyses assessed by IHC (supplementary data S6, available at *Annals of Oncology* online).

discussion

We investigated cetuximab in the pre-operative window period in treatment-naïve SCCHN patients selected for primary curative surgery. Our study shows that pre-operative cetuximab infusion is safe and induces a high rate of ^{18}F FDG-PET response.

Given that cetuximab may have anti-angiogenic properties and has a long elimination half-life (mean: 112 h, range: 63–230), the primary end point of our trial was safety. With the exception of one patient with post-operative bleeding, we did not observe any significant surgical toxic effects, even when cetuximab was infused 24 h before surgery. However, a careful review of the medical history of this patient revealed that she

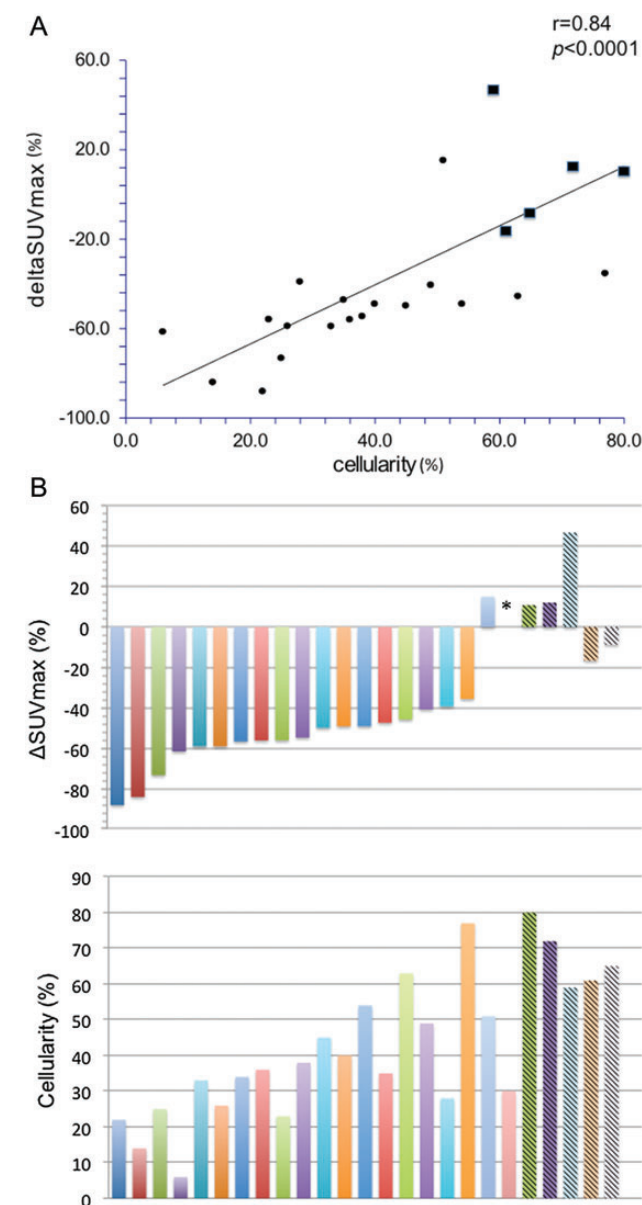


Figure 1. (A) Correlation between $\Delta\text{SUV}_{\text{max}}$ and tumour cellularity (•patients in the cetuximab group, ■ patients in the control group). (B) Individual response for the patients included in the expansion part ($n = 19$) and in the control groups ($n = 5$). Each bar represents an individual patient. Hatched bars = control patients; filled bars = patients treated with cetuximab; * = patient without evaluable ^{18}F FDG-PET.

had experienced a similar acute post-operative bleeding complication 10 years before, suggesting that she may have a predisposition to bleed. Other groups have documented the safety of cetuximab when administered before colorectal liver metastasis surgery [5, 6]. However, the interval between the last infusion and surgery was longer: 12–56 days and 4–6 weeks, respectively.

‘Window’ pre-operative studies are not without potential issues. It is crucial to perform surgery with curative intent within an acceptable delay after diagnosis to avoid any possible negative impact on the oncological outcome. Some studies

suggest that SCCHN curative treatment should be carried out within 20–28 days following diagnosis [7]. Our study design took into account all these parameters. Other pre-operative window studies have been reported with anti-HER therapies in SCCHN patients: one with erlotinib and the other with lapatinib [8, 9]. Both trials were pioneering, but the duration of treatment differed from one patient to another resulting in less standardized translational procedures and variations in the timing of imaging and tissue sample collection.

Pre-clinical and clinical studies support the use of ^{18}F FDG-PET to evaluate the activity of EGFR inhibitors [10, 11]. In some studies, a ^{18}F FDG-PET response was associated with tumour shrinkage or improved time to progression [11, 12]. According to EORTC, 90% of our cetuximab-treated patients had a ^{18}F FDG-PET response, thereby supporting further investigation of cetuximab in this setting. Different speculative explanations may explain the unexpected high ^{18}F FDG-PET response rate observed in our trial: SCCHN is a highly metabolic tumour; the last cetuximab infusion was injected 2 h before the second ^{18}F FDG-PET and the study population was treatment naïve.

Interestingly, we found a correlation between $\Delta\text{SUV}_{\text{max}}$ and residual tumour cellularity in the resected specimens. For patients with $\Delta\text{SUV}_{\text{max}} < -25\%$ or $< -50\%$, Ki67 was significantly decreased after cetuximab treatment. Altogether, these data suggest that ^{18}F FDG-PET deserves further investigation as a potential early marker of cetuximab activity

in SCCHN. In pre-operative SCCHN studies with erlotinib or lapatinib, significant activity was also detected by ^{18}F FDG-PET [9, 13–15]. Unfortunately, a comparison between these study results is difficult due to the absence of consensus guidelines concerning the evaluation of ^{18}F FDG-PET responses in SCCHN.

In contrast to metabolic response, significant tumour shrinkage was recorded in only 2 (14%) of 14 patients with measurable disease. This is within range of the PR rate recorded with cetuximab monotherapy in palliative SCCHN [16]. Interestingly, some of our patients showed an important decrease in Ki67 expression and/or low tumour cellularity without any significant modification of their tumour size (Figure 2). Although speculative, it is possible that modifications in the tumour's composition could explain why ^{18}F FDG-PET is more accurate in detecting tumour responses than conventional imaging. Indeed, the decrease in tumour cellularity was associated with more fibrosis (data not shown supplementary data, available at *Annals of Oncology* online). These findings reinforce the fact that RECIST criteria are probably not the best way to evaluate the efficacy of targeted agents. Diffusion-Weighted MRI may represent an interesting alternative, as suggested by our exploratory data that showed an apparent diffusion coefficient (ADC) increase in three out of four patients after cetuximab (data not shown and supplementary data S7, available at *Annals of Oncology* online).

In conclusion, the design and results of this study strongly support future SCCHN studies involving a 'window' pre-

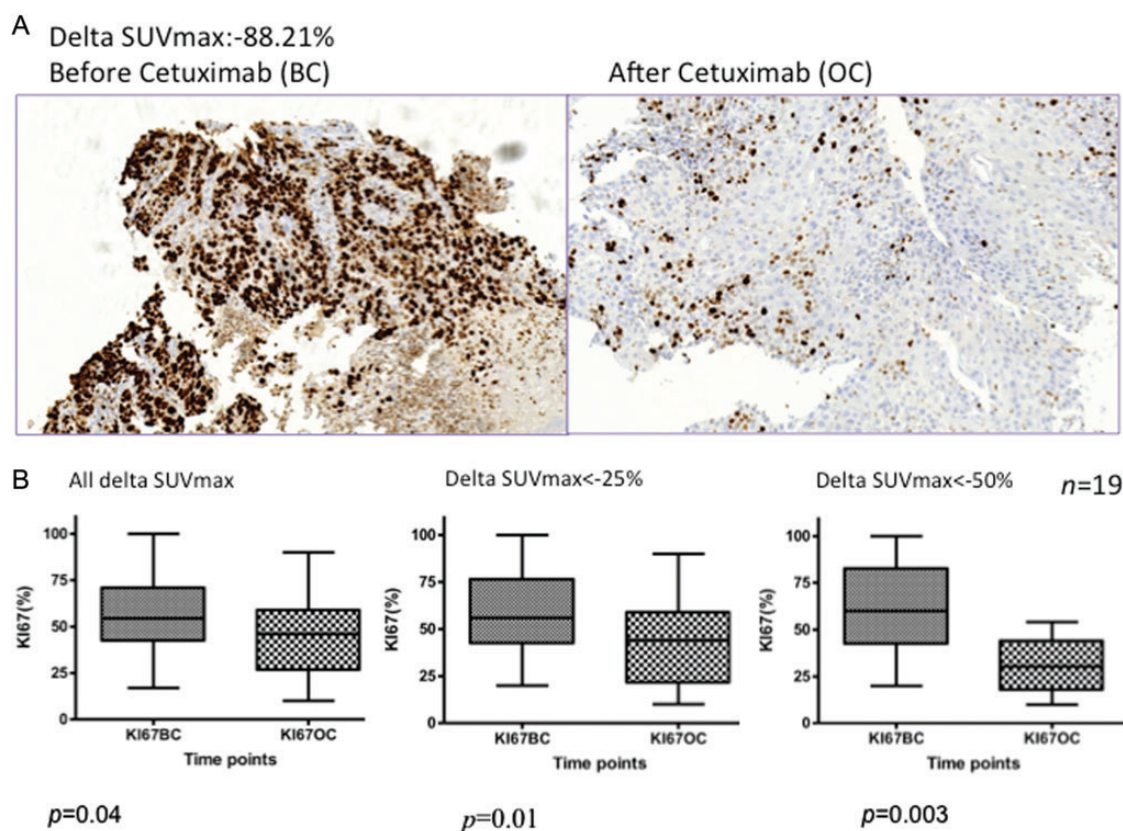


Figure 2. (A) Ki67 staining before (BC) and after (OC) cetuximab in a patient with $\Delta\text{SUV}_{\text{max}}$ of -88% . (B) Ki67 (box plot) before (BC) and after (OC) cetuximab in relation to $\Delta\text{SUV}_{\text{max}}$ for the expansion group ($n = 19$) and the subgroup of patients with $\Delta\text{SUV}_{\text{max}} < -25\%$ ($n = 18$) and $\Delta\text{SUV}_{\text{max}} < -50\%$ ($n = 10$).

operative approach in a multicentre setting. We have demonstrated that this approach is safe and feasible. Further analyses on biopsies collected before and after treatment are ongoing to better comprehend the pharmacodynamic effects of cetuximab. These new insights may help generate hypotheses regarding treatment resistance mechanisms.

acknowledgements

The authors thank Aileen Eiszele for editing the manuscript.

funding

This was an investigator-driven study (Sponsor and promotor: Cliniques universitaires Saint-Luc, Brussels) funded by Fondation Maisin (Université catholique de Louvain, Belgium) and an unrestricted grant from Merck Serono. Sandra Schmitz received a fellowship from Fonds Spécial de Recherche (FSR, Université catholique de Louvain, Brussels) and Fondation Saint-Luc (Cliniques universitaires Saint-Luc, Brussels).

disclosure

J-P Machiels received a grant and drug donation from Merck Serono to conduct this trial. Merck Serono had no role in the trial design, the collection and interpretation of data, nor in the writing of this article. Merck Serono has carried out a scientific review of the publication, but the views and opinions described in the publication do not necessarily reflect those of Merck Serono. SS, MH, HR, MM, BW, RL, FXH, TD, NM, DR, ML, NC, AG have declared no conflicts of interest.

references

- Bonner JA, Harari PM, Giral J et al. Radiotherapy plus cetuximab for squamous-cell carcinoma of the head and neck. *N Engl J Med* 2006; 354: 567–578.
- Vermorken JB, Mesia R, Rivera F et al. Platinum-based chemotherapy plus cetuximab in head and neck cancer. *N Engl J Med* 2008; 359: 1116–1127.
- Young H, Baum R, Cremerius U et al. Measurement of clinical and subclinical tumour response using [18F]-fluorodeoxyglucose and positron emission tomography: review and 1999 EORTC recommendations. European Organization for Research and Treatment of Cancer (EORTC) PET Study Group. *Eur J Cancer* 1999; 35: 1773–1782.
- Fleming TR. One-sample multiple testing procedure for phase II clinical trials. *Biometrics* 1982; 38: 143–151.
- Pessaix P, Marzano E, Casnedi S et al. Histological outcome after preoperative cetuximab: case-matched control study. *World J Surg* 2010; 34: 2765–2772.
- Neeff HP, Drogwitz O, Klock A et al. Impact of preoperative targeted therapy on postoperative complications after resection of colorectal liver metastasis. *Int J Colorectal Dis* 2012; 27: 635–645.
- Primdahl H, Nielsen AL, Larsen S et al. Changes from 1992 to 2002 in the pretreatment delay for patients with squamous cell carcinoma of larynx or pharynx: a Danish nationwide survey from DAHANABO. *Acta Oncol* 2006; 45: 156–161.
- Thomas F, Rochoix P, Benlyazid A et al. Pilot study of neoadjuvant treatment with erlotinib in nonmetastatic head and neck squamous cell carcinoma. *Clin Cancer Res* 2007; 13: 7086–7092.
- Del Campo JM, Hitt R, Sebastian P et al. Effects of lapatinib monotherapy: results of a randomised phase II study in therapy-naïve patients with locally advanced squamous cell carcinoma of the head and neck. *Br J Cancer* 2011; 105: 618–627.
- Sunaga N, Oriuchi N, Kaira K et al. Usefulness of FDG-PET for early prediction of the response to gefitinib in non-small cell lung cancer. *Lung Cancer* 2008; 59: 203–210.
- Di Fabio F, Pinto C, Rojas Limpe FL et al. The predictive value of 18F-FDG- PET early evaluation in patients with metastatic gastric adenocarcinoma treated with chemotherapy plus cetuximab. *Gastric Cancer* 2007; 10: 221–227.
- Vergez S, Delord JP, Thomas F et al. Preclinical and clinical evidence that deoxy-2-[18F]fluoro-D-glucose positron emission tomography with computed tomography is a reliable tool for the detection of early molecular responses to erlotinib in head and neck cancer. *Clin Cancer Res* 2010; 16: 4434–4445.
- Mileskin L, Hicks RJ, Hughes BG et al. Changes in 18F-fluorodeoxyglucose and 18F-fluorodeoxythymidine positron emission tomography imaging in patients with non-small cell lung cancer treated with erlotinib. *Clin Cancer Res* 2011; 17: 3304–3315.
- Zander T, Scheffler M, Nogova L et al. Early prediction of nonprogression in advanced non-small-cell lung cancer treated with erlotinib by using [(18)F] fluorodeoxyglucose and [(18)F]fluorothymidine positron emission tomography. *J Clin Oncol* 2011; 29: 1701–1708.
- Vermorken JB, Herbst RS, Leon X et al. Overview of the efficacy of cetuximab in recurrent and/or metastatic squamous cell carcinoma of the head and neck in patients who previously failed platinum-based therapies. *Cancer* 2008; 112: 2710–2719.