

PRELIMINARY RESULTS OF SAFETY AND EFFICACY OF THE TREATMENT WITH INTRAVITREAL INJECTION OF ETAMSYLATE IN AGE-RELATED MACULAR DEGENERATION (ARMD).

INTRODUCTION

The age-related macular degeneration (AMD) is a very frequent ocular pathology; being the main cause of loss of vision after the age of 50 years. The prevalence is increasing progressively, as life expectancy increases, especially with the gain of the population of over 80 years. An epidemiology study ([Spanish Eyes Epidemiological \[SEE\] Study Group 2011](#)), detected a prevalence of the AMD in Spain of 3.4% that was also increasing with the age.

The macula is a small rounded area, located close to the centre of the retina which with age is degenerating. Frequently this degeneration is bilateral, although severity might be different. The most common sign is the view of a blurred zone near the central area of vision.

The AMD degenerates in two phases, resulting in two types of pathological processes: Dry AMD: is the initial phase and affects to 80-90% of patients, and AMD wet or exudative: usually originated in a later stage of progression of dry AMD, with the creation of new vessels (or neovascularization) in the retina.

The assessment of visual acuity provides an objective evaluation of the patient's clinical status with AMD and its response to treatments. The loss of central vision caused by AMD is associated with a significant deterioration in the quality of life of patients, since it significantly interferes with activities of daily life, in basic activities and with social and work performance: housework, writing, driving, recognizing faces, etc.

In relation with the different treatments, actually there is no treatment available for dry AMD and the usual approved treatment for AMD is the intravitreal injections of drugs that inhibit vascular endothelial growth factor (VEGF) activity. Although intravitreal injection of anti-VEGF drugs may reduce retinal oedema within the first two months after treatment, its chronic use may be associated with adverse (in many cases significant) both ocular and systemic effects, by altering normal physiological function of the endothelium of the ocular and extra-ocular blood vessels.

The investigational drug is etamsylate (diethylammonium 2,5-dihydroxybenzene sulfonate) is not a new drug, since it was authorized in Spain from 1959 until February 2015 for indications related to bleeding.

The main mechanism of action of etamsylate is to inhibit the effect of fibroblast growth factor (FGF) a protein that is also in greater amounts in the eyes of people with macular degeneration. This factor is directly involved in the two forms of AMD (dry and exudative) for their pro-inflammatory and proangiogenic activities (Thomas et al. 1985; Andrés et al. 2009; de Oliveira Dias et al. 2011); this means that the FGF participates in processes that are harmful to the eye, such as inflammation and the formation of new capillaries. Therefore, local inhibition of FGF overexpressed in AMD is a new therapeutic pathway of great clinical interest.

Over the last years, members of the research Group of the present clinical study had synthesized different inhibitors of FGF and its receptor (FGFR), with capacity to neutralize the proinflammatory

and proangiogenic activities related to the activation of the FGF / FGFR system. Among the molecules synthesized and studied, 2,5-dihydroxybenzenesulfonate was shown to be the most potent inhibitor of FGF. Two salts of this molecule are etamsylate (diethylammonium 2,5-dihydroxybenzene sulfonate) and dobesylate (calcium 2,5-dihydroxybenzene sulfonate).

STUDY OBJECTIVES

According to the aforementioned rationale, we have established three Groups:

Trial 1. Phase IV-II. This First Study allows the assessment of the efficacy and safety of intravitreal injection of etamsylate through the objectives detailed in the following sections.

The main objective was to assess the efficacy after 4 weeks of a single intravitreal injection of etamsylate in the improvement of visual acuity in patients diagnosed with dry or exudative AMD.

Trial 2. This is an open retreatment study that includes those patients that have previously entered in the Clinical Trial Phase IV-II, performed to assess the efficacy and safety of intravitreal etamsylate injection for the treatment of dry/exudative AMD after 16 weeks of a single intravitreal injection and that after at least 4 weeks have not shown response to the treatment.

The main objective was to assess the effect of intravitreal administration of etamsylate up to week 48 on the efficacy in the improvement of the visual acuity, to reverse the structural changes of the retina associated to AMD, to contrast

sensitivity and, last, to patient's quality of life.

Trial 3. This is an extension study of the Clinical Trial Phase IV-II performed to assess the efficacy and safety of intravitreal etamsylate injection for the treatment of dry/exudative AMD after 16 weeks of a single intravitreal injection.

The main objective is to assess the effect of treatment received in the previous clinical trial (intravitreal injection of etamsylate or sham treatment) in the improvement of visual acuity in patients diagnosed with dry or exudative AMD after non-interventional follow up of "eye treated" in the clinical trial up to week 48 after the double-blind treatment.

MATERIAL & METHODS

Patients Trial 1

STUDY POPULATION: the target population of the present clinical trial are patients with dry/exudative AMD who are seeking medical treatment and are compliant with the inclusion criteria established in the protocol.

Patients Trial 2

STUDY POPULATION: the target population of the present clinical trial are patients with dry/exudative AMD that finished the double-blind study designed to assess the efficacy and safety of the treatment with intravitreal injection of etamsylate and are compliant with the inclusion criteria established to participate in this retreatment study.

Patients Trial 3

STUDY POPULATION: the target population of the present clinical trial are patients with dry/exudative AMD that finished the double-blind study designed to assess the efficacy and safety of the treatment with intravitreal injection of etamsylate and are compliant with the inclusion criteria established to participate in this extension study.

Method

In these trials, Dicynone® 250 mg/2 ml, by Sanofi-Aventis lab (Paris, France)

will be used. It is commercialised in liquid form in an adjacent country of the European Union (and therefore compliant with the same European regulations as Spain for the registry and manufacturing of drugs for human use). It is presented in glass ampoules containing 2 mL of solution for injection in packs of 6 or 50 ampoules. The data of the technical sheet are included in the Investigator's Brochure.

The possible clinical benefits of intravitreal injection of etamsylate in AMD treatment, as a new therapeutic indication for etamsylate, was investigated.

STATISTICAL ANALYSIS

All registered variables are summarized in tables including the appropriate descriptive statistical methods (measures of central tendency and dispersion, and absolute and relative frequencies, as appropriate). Inferences were made to estimate the parameters of the population distributions by calculating the 95% bilateral confidence intervals.

Finally, the baseline data is described for the entire sample, separately in each subsample, and separately in each treatment Group of each subsample.

RESULTS

The study diagram is included as figure 1.

Selected sample.

Database includes 48 patients, of which 4 of them were finally not considered as they were screen failures.

We have recruited 44 patients divided into 2 groups; one treated with etamsylate and the other with sham treatment (control Group). They have been randomized G1; 21 patients and G2; 23 patients and all of them has been considered for safety study.

Out of the 44 patients of the safety analysis Group, there are 3 patients that even if they received etamsylate, are not evaluable.

Therefore, for the Intention to Treat (IIT) analysis group we have 41 patients for whom we have a valid evaluation of visual acuity.

There is a great number of patients with major deviations, so we needed to work with the **per protocol analysis Groups**, which leaves only 31 evaluable patients compliant with inclusion criteria and having a valid follow up. G1; 16 patients and G2; 15 patients

Regarding descriptive statistics, the mean age of the patients in Group 1 was 76 years and for Group 2, mean age was 78 years old. If we look at gender, 19% of patients in Group 1 were male and 17% in Group 2.

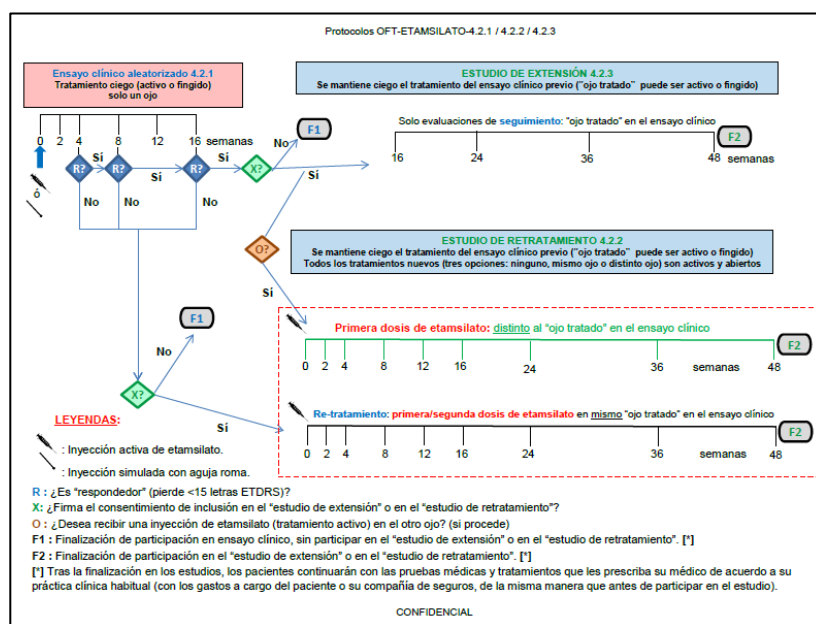


Figure 1. Study Diagram

Regarding treated eyes, right eye was treated for 52% of patients from Group 1 and 39% of patients from Group 2. Concerning AMD type, the majority of patients in both groups suffered from exudative AMD, specifically, 66% from Group 1 and 65% of Group 2. In relation to race, all patients but one, were Caucasian. It is remarkable that 3 patients from Group 1 had family history of AMD. Between 60 and 70% of the patients in the two groups were non-smokers, and between 85 and 90% of the patients labour situation was retired patients.

Taking a look at medical background, there were 12 and 10 patients respectively who suffered of a concomitant systemic disease. If we look deeper into other age-related diseases [arterial hypertension (HTA), diabetes (DBT), Chronic obstructive pulmonary disease (EPOC), cardiovascular disease (ECV), hypercholesterolemia (HCOL), osteoporosis (OST)], there was a 13% of patients suffering from them in both groups.

Study Objectives

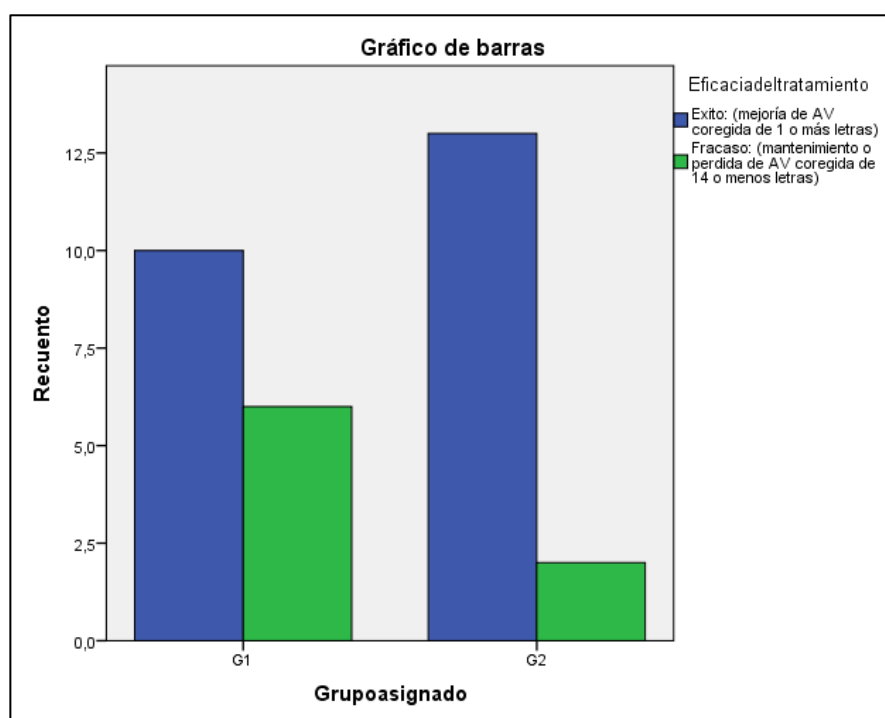
This is a proof of concept study to evaluate the efficacy and safety of intravitreal etamsylate to treat dry or exudative AMD. Its design will allow short term evaluation (4 ad 16 weeks) of the effects of intravitreal etamsylate with the aim to establish the adequacy of this treatment for AMD.

Treatment Evaluation

“Treatment success” is defined as a best corrected visual acuity of 1 or more letters in the ETDRS optotype in comparison with baseline.

“Treatment failure”, as opposed to “treatment success”, is defined as the absence of changes in the best corrected visual acuity or as the loss of 1 or more letters in the ETDRS optotype in comparison with baseline.

“Treatment response” is defined as the improvement, maintenance or loss of a best corrected visual acuity of less than 15 letters in the ETDRS optotype in comparison with baseline.



Graph 1. Efficacy of the treatment of patients at week 4.

“No response to treatment”, as opposed to “treatment response”, is defined as the loss of 15 or more letters in the ETDRS optotype of best corrected visual acuity in comparison with baseline.

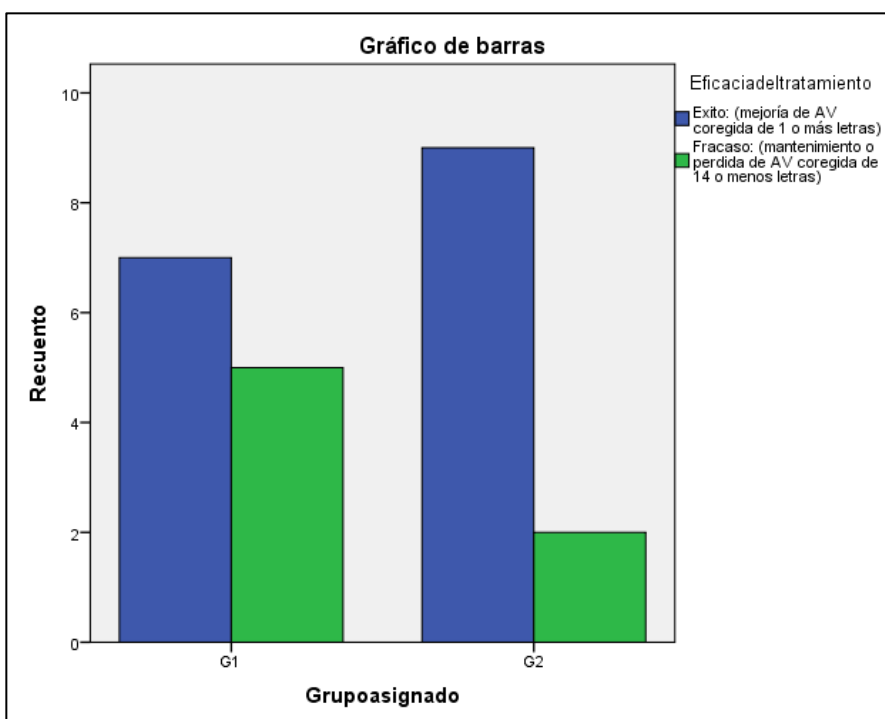
Primary Endpoint

To establish efficacy at 4 weeks of a single intravitreal injection of etamsylate in

the improvement of visual acuity in patients diagnosed with dry or exudative DMAE.

Response to the treatment at Week 4

In both groups, all patients (100% respond to treatment, i.e. all improve or have a loss of visual acuity less than 14 letters.



Graph2: Efficacy of the treatment of patients at week 16.

Efficacy of the treatment Week 4.

Graph 1 shows the efficacy of the treatment of patients in both groups.

Secondary Endpoint

Evaluate the efficacy at 16 weeks of a single intravitreal injection of etamsylate in improving visual acuity in patients diagnosed with dry or exudative AMD.

Response to Treatment. Week 16.

In the 2 groups, all patients (100%) respond to treatment, i.e. all improve or have a loss of visual acuity less than 14 letters.

Efficacy of the treatment Week 16.

Graph 2 shows the efficacy of the treatment of patients in both groups.

It is shown that there is no significant difference between groups in terms of efficacy considering the criterion established in the protocol success/failure.

This was a dichotomous criterion based on a non-dichotomous test, therefore we believed the results obtained in the trial with that test, undoubtedly allowed for a more complex statistical evaluation and establish more concrete variations between the groups, where the early termination should have had no negative impact on the evaluation of results, and we decided to continue with that assessment, which we also present in this document.

Evolution of the increase in the number of letters in week 4.

As shown in Table 1, taking into account the increase in the number of letters improved per patient, it was found that in Group 1, at 4 weeks, 80% of patients improved, with an average of 5,875 letters in patients that improved, and in Group 2, 71.42% of the patients improved, with an average of 6.26 letters, in patients that improved.

Divided by type of DMAE, the Group 1 patients with exudative AMD at 4 weeks improved by 76.9% on average of 6.3 letters and those in Group 2, an average of 6 letters in 56.25% of the patients. patients. (Table 2).

Group	Result	4 weeks			16 weeks		
		# Patients	%	Letters Avg.	# Patients	%	Letters Avg.
G1	↑→	16	80%	5.87	11	68.75%	9.9
	↓	4	20%	-4.75	5	31.25%	-8
G2	↑→	15	71.43%	6.26	11	73.33%	6.27
	↓	6	28.57%	-4.3	4	26.66%	-5.25

Table 1 Total. Number of letters increase

Patients with dry AMD, in those same 4 weeks, improved an average of 5.1 letters in 85.71% of the patients in Group 1, and an average of 6.6 letters in the same 85.71% of the patients from Group 2. (Table 3).

three clinical trials, where in the first one it was administered intravitreal etamsylate to a cohort of patients with ARMD recruited in a period of 24 months approximately.

Group	Result	4 weeks			16 weeks		
		# Patients	%	Letters Avg.	# Patients	%	Letters Avg.
G1	↑→	10	76.92%	6	7	63.63%	11
	↓	3	23.08%	-5.3	4	36.37%	-8
G2	↑→	9	64.28%	6	7	77.77%	6.7
	↓	5	35.72%	-3.8	2	22.23%	-6.5

Table 2. Wet ARMD. Number of letters increase

Evolution of the increase in the number of letters in week 16.

At week 16, improvement was maintained in both groups of patients, improving 68.75% of Group 1 patients, with a mean of up to 9.9 letters and 73.33% of Group 2 patients, with an average of 6.27 letters. (Table 1).

As mentioned above, the complete study objective was to evaluate the efficacy and safety of the treatment with intravitreal etamsylate in patients with age-related macular degeneration (ARMD). In this report, we analyze the data obtained from the first clinical trials where we evaluate the intravitreal injection safety

Group	Result	4 weeks			16 weeks		
		# Patients	%	Letters Avg.	# Patients	%	Letters Avg.
G1	↑→	6	85.72%	5.1	4	80%	6.75
	↓	1	14.28%	-3	1	20%	-8
G2	↑→	6	85.72%	6.6	4	66.66%	5.5
	↓	1	14.28%	-7	2	33.34%	-4

Table 3. Dry ARMD. Number of letters increase

If we divide by type of DMAE, Group 1 patients with exudative AMD, improved or maintained an average of 11.6 letters in 63.63% of the patients, and those in Group 2 improved 77.77%, and an average of 6.7 letters. (Table 2).

In dry AMD, at 16 weeks, patients from Group 1 improved or maintained the number of read letters in 80% of patients, with a mean of 6.75 letters, and in Group 2, 66.66% of patients maintained or improved, an average of 5.5 letters. (Table 3).

DISCUSSION

The present report presents the clinical results of a complete study, including

and the disease efficacy in weeks 4 and 16. Both following studies were retreatment and extension.

The trial referred in this document, was closed prematurely approximated after two years, for different reasons; the recruitment was really slow, not because of the disease incidence but due to complications derived from the protocol design (inclusion criteria, high number of follow up visits, complexity of the calendar, a single unique site...), so the study started to be extended in time more than expected.

On the other hand, we considered that the protocol did not fulfil the raised expectations, since in the valuation of the visual acuity valuing the change of a single letter of the ETDRS optotype, it seemed not to be so reliable.

In addition, it was clear that the disease, even in its most aggressive and fast form (wet), degenerated so rapidly that the loss of visual acuity at the time marked in the protocol, main objective 4 weeks, was evident.

Finally, we did not manage to extend the protocol to other sites that in our opinion would have been important for a better development of our trials

For all these reasons, together with the interest that began to raise in some forums for the new indication of the molecule (intravitreal etamsylate), we decided to do an intermediate statistical analysis.

When performing this intermediate statistical analysis of the results, we detected that, with the criteria established in the protocol for the evaluation of the main objective, there was no significant difference between the groups, which is the reason why we decided to stop the study.

Regarding safety data during all the study, only one patient presented an Adverse Effect. It was a patient in whom was observed during the review of the visit 4, an ocular hypertension that was treated. These safety data are consistent with the findings in the investigators' experience regarding the safety of intravitreal etamsylate administration, and found only one adverse event (vitreous hemorrhage related to the injection itself).

Despite the not very gratifying clinical results, we could observe that there were differences between group 1 and group 2 not in the improvement, success or failure since both groups improved but in the number of letters, since Group 1 improved in 3.75 letters in week 4 and 4.31 letters in week 16 while those in Group 2 improved 3.23 letters in week 4 and 3.2 letters in week 16.

Another thing that caught our attention is that those patients who worsened in both groups were mostly patients who suffered the disease in later stages at the initiation visit and almost all of them suffered the disease in its most aggressive (exudative) form. This makes us consider evaluating in new trials to analyze if intravitreal Etamsylate is more effective in those patients in the early stages of the disease.

Regarding the improvement in both groups of patients, we are forced on the one hand to define ranges of numbers in the optotype to consider success or failure of the treatment of the disease and on the other hand to assess the normal time of evolution of the disease, as it seems to be slower than anticipated in our previous protocol.

Finally, in those patients who responded to the treatment, they improved at 16 weeks, but later there was a worsening of the improvement, although never reached the basal level, so that along with the bibliographical data of the literature validated with this and other treatments it seems important conducting retreatment and extension studies.

These approaches along with those in which an individualized treatment is valued in which the decision of each injection and the treatment interval is based on the patient's response to the last injection are gaining in popularity among retinal specialists and published results on vision and stability of the disease show that it is a safe and efficient treatment approach.

Shorter intervals between injections may result in a more timely response to recurrences and an inevitable increase in the number of injections that could have improved results.

CONCLUSION

This study has demonstrated that there is safety in the intravitreal injection of etamsylate since no adverse effects have been detected in any of the study patients related to the drug nor with the procedure used, the risk can be assessed as practically nil, compared to a high benefit if we

confirm the good results obtained by working with the full potential of the test in new trials.

Certainly, further studies are needed to report on the beneficial impact of this treatment and therefore the possible change in treatment strategy in AMD in usual clinical practice.

REFERENCES

- Adelman RA, Zheng Q, Mayer HR. Persistent ocular hypertension following intravitreal bevacizumab and ranibizumab injections. *J Ocul Pharmacol Ther.* 2010; 26:105-10.
- Ambati J, Ambati BK, Yoo SH, Ianchulev S, Adamis AP. Age-related macular degeneration: etiology, pathogenesis, and therapeutic strategies. *Surv Ophthalmol.* 2003; 48:257-93.
- Amin R, Puklin JE, Frank RN. Growth factor localization in choroidal neovascular membranes of age-related macular degeneration. *Invest Ophthalmol Vis Sci.* 1994; 35:3178-88.
- Angulo J, Cuevas P, Cuevas B, El Youssef M, Fernández A, Martínez-Salamanca E, González-Corrochano R, Giménez-Gallego G. Diacetyloxyl derivatization of the fibroblast growth factor inhibitor dobesilate enhances its anti-inflammatory, anti-angiogenic and anti-tumoral activities. *J Transl Med.* 2015; 13:48.
- Byeon SH, Lee SC, Choi SH, Lee HK, Lee JH, Chu YK, Kwon OW. Vascular endothelial growth factor as an autocrine survival factor for retinal pigment epithelial cells under oxidative stress via the VEGF-R2/PI3K/Akt. *Invest Ophthalmol Vis Sci.* 2010; 51:1190-7.
- Cuevas P(a), Outeiriño LA, Azanza C, Angulo J, Giménez-Gallego G. Clinical efficacy of intravitreal injection of Dobesilate for reversing choroidal angiogenesis in age-related macular degeneration. *J Aging Ger.* 2013, 1, 1-8
- Cuevas P(b), Outeiriño LA, Azanza C, Angulo J, Giménez-Gallego G. Intravitreal Dobesilate treatment of dry age-related macular degeneration: 12 months' results. *J Ocul Dis Ther* 2014; 2: 1-6.

- Cuevas P(c), Outeiriño LA, Azanza C, Giménez-Gallego G. Durable recovery of the macular architecture and functionality of a diagnosed age-related macular degeneration 1 year after a single intravitreal injection of dobesilate. *BMJ Case Rep* 2013, doi 10.1136/bcr-20113-010203
- Cuevas P(d), Outeiriño LA, Azanza C, Angulo J, Giménez-Gallego G. Dobesilate for dry age-related macular degeneration. *J Biomed Sci Eng*.2013; 6: 8-14
- Daniel E, Toth CA, Grunwald JE, Jaffe GJ, Martin DF, Fine SL, Huang J, Ying GS, Hagstrom SA, Winter K, Maguire MG; Comparison of Age-related Macular Degeneration
- de Oliveira Dias, J. R., E. B. Rodrigues, M. Maia, O. Magalhaes, Jr., F. M. Penha and M. E. Farah (2011). "Cytokines in neovascular age-related macular degeneration: fundamentals of targeted combination therapy." *Br J Ophthalmol* 95: 1631-1637.
- Donoso LA, Kim D, Frost A, Callahan A, Hageman G. The role of inflammation in the pathogenesis of age-related macular degeneration. *Surv Ophthalmol*. 2006; 51:137-52.
- Eremina V, Jefferson JA, Kowalewska J, Hochster H, Haas M, Weisstuch J, Richardson C, Kopp JB, Kabir MG, Backx PH, Gerber HP, Ferrara N, Barisoni L, Alpers CE, Quaggin SE. VEGF inhibition and renal thrombotic microangiopathy. *Eng J Med*. 2008; 358:1129-36
- Fernández IS, Cuevas P, Angulo J, López-Navajas P, Canales-Mayordomo A, González-Corrochano R, Lozano RM, Valverde S, Jiménez-Barbero J, Romero A, Giménez-Gallego G. Gentisic acid, a compound associated with plant defense and a metabolite of aspirin, heads a new class of in vivo fibroblast growth factor inhibitors. *J Biol Chem*. 2010; 285:11714-29.
- Frank RN. Growth factors in age-related macular degeneration: pathogenic and therapeutic implications. *Ophthalmic Res*. 1997; 29:341-53.
- Meyer T, Robles-Carrillo L, Robson T, Langer F, Desai H, Davila M, Amaya M, Francis JL, Amirkhosravi A. Bevacizumab immune complexes activate platelets and induce thrombosis in FCGR2A transgenic mice. *J Thromb Haemost*. 2009; 7:171-81.
- Oladipupo SS, Smith C, Santeford A, Park C, Sene A, Wiley LA, Osei-Owusu P, Hsu J, Zapata N, Liu F, Nakamura R, Lavine KJ, Blumer KJ, Choi K, Apte RS, Ornitz DM. Endothelial cell FGF signaling is required for injury response but not for vascular homeostasis. *Proc Natl Acad Sci U S A*. 2014; 111:13379-84.
- Papadopoulou DN, Mendrinou E, Mangioris G, Donati G, Pournaras CJ. Intravitreal ranibizumab may induce retinal arteriolar vasoconstriction in patients with neovascular age-related macular degeneration. *Ophthalmology*. 2009; 116:1755-61
- Peters S, Heiduschka P, Julien S, Ziemssen F, Fietz H, Bartz-Schmidt KU; Tübingen Bevacizumab Study Group, Schraermeyer U. Ultrastructural findings in the primate eye after intravitreal injection of bevacizumab. *Am J Ophthalmol*. 2007; 143:995-1002
- Prager GW1, Breuss JM, Steurer S, Mihaly J, Binder BR. Vascular endothelial growth factor (VEGF) induces rapid prourokinase (pro-uPA) activation on the surface of endothelial cells. *Blood*. 2004; 103:955-62.
- Quaggin SE. Turning a blind eye to anti-VEGF toxicities. *J Clin Invest*. 2012; 122:3849-51.
- Ridwan S, Bauer H, Frauenknecht K, von Pein H, Sommer CJ. Distribution of granulocyte-monocyte colony-stimulating factor and its receptor α -subunit in the adult human brain with specific reference to Alzheimer's disease. *J Neural Transm (Vienna)*. 2012; 119:1389-406.
- Sacu S, Pemp B, Weigert G, Matt G, Garhofer G, Prunte C, Schmetterer L, Schmidt-Erfurth U. Response of retinal vessels and retrobulbar hemodynamics to intravitreal anti-VEGF treatment in eyes with branch retinal vein occlusion. *Invest Ophthalmol Vis Sci*. 2011; 52:3046-50.
- Soliman W, Vinten M, Sander B, Soliman KA, Yehya S, Rahman MS, Larsen M. Optical coherence tomography and vessel diameter changes after intravitreal bevacizumab in diabetic macular oedema. *Act Ophthalmol*. 2008; 86:365-71
- Stewart MW. The expanding role of vascular endothelial growth factor inhibitors in ophthalmology. *Mayo Clin Proc*. 2012; 87:77-88.
- Vidinova C, Vidinov N. [The effect of bevacizumab on the ultrastructure of choroidal neovascular membranes in patients with age-related macular degeneration (DMAE)]. *Klin Monbl Augenheilkd*. 2009; 226:491-5.