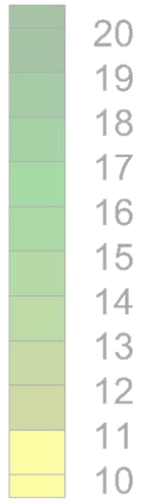



Regional iVbv changes [%]



Effect of iNO and vasodilation in COPD patients



EXECUTIVE SUMMARY - PULSE-COPD-007

STUDY TEAM

Dennis Belmans
Glenn Leemans
Cedric Van Holsbeke
Katherine Barboza
Wilfried De Backer
Jan De Backer

Contact:
FLUIDDA, Inc.
228 East 45th Street
9th Floor, Suite 9E
New York, NY 10017
katherine.barboza@fluidda.com

- The **aim** of this exploratory study is to examine the utility of high resolution computed tomography (HRCT) to measure changes in functional pulmonary imaging parameters as a function of long term iNO administration using the device INOpulse for 4 weeks in relation to Patient Reported Outcome (PRO) and exercise tolerance in subjects with WHO Group 3 PH associated with COPD on LTOT.
- Changes from baseline to acute, and 4 weeks of pulsed iNO and after 2 weeks of withdrawal from pulsed iNO will be evaluated.
- Primary endpoint is the acute change in lobar blood volume (mL) at TLC with iNO and the change after 4 weeks of treatment

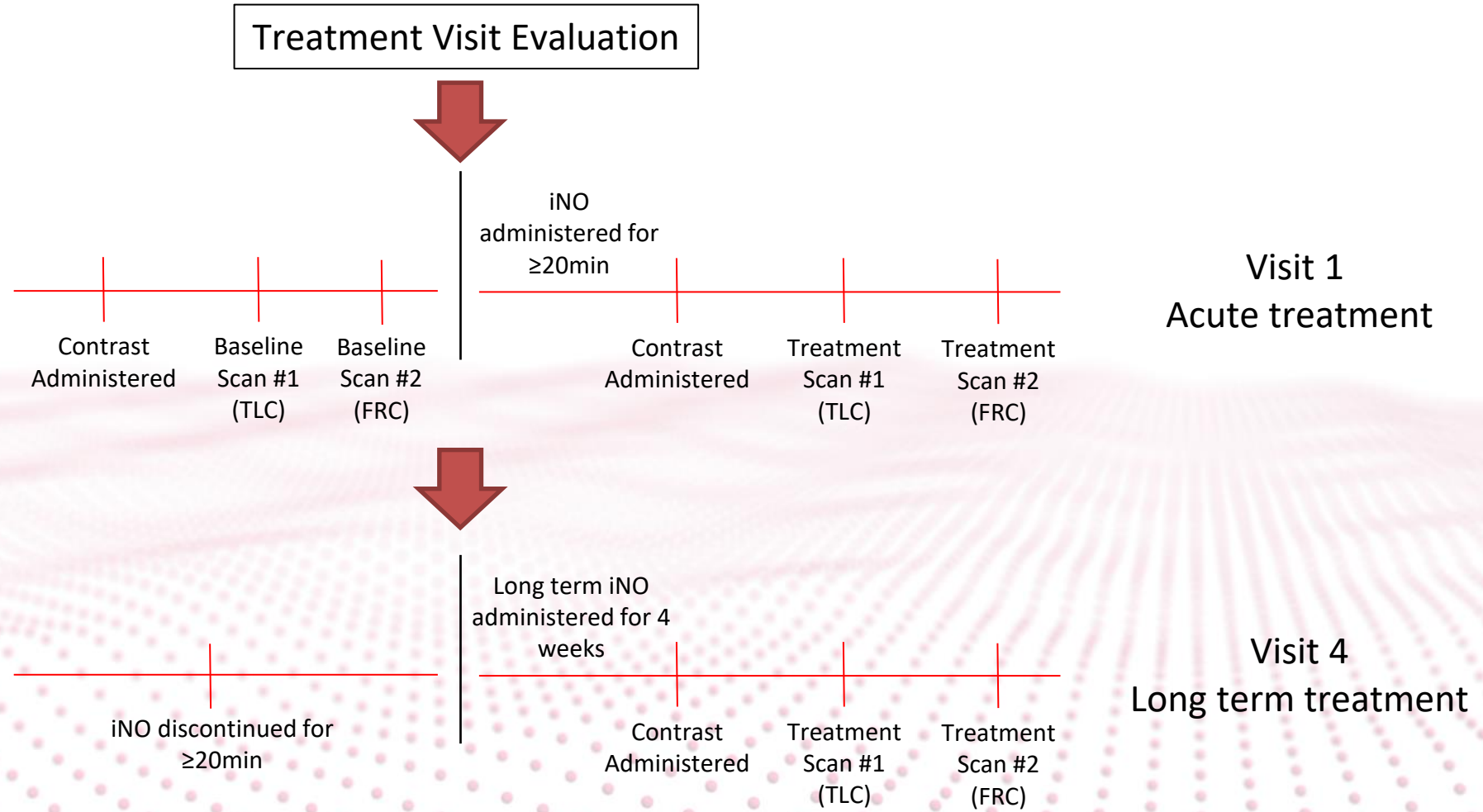
OBJECTIVES

- Secondary endpoints (FRI):
 - Blood vessel % and density on lobar level
 - Total lung volume at TLC
 - Lobar volumes at TLC
 - Internal airflow distribution
 - Airway volume down to generation 8-10 at TLC
 - Computational Fluid Dynamics (CFD)-based resistance on lobar level
 - Ventilation/perfusion (V/Q) matching
- Secondary endpoints (Clinical):
 - Spirometry
 - 6MWT
 - PRO
 - 2D Echocardiogram
- Safety endpoint
 - Incidence of all relevant AE, AEs and device deficiencies that result in AE or SAE

SCHEDULE OF ASSESSMENTS

TRIAL PERIOD	Screening	Treatment				Follow-up
	Day -30-0	Visit 1	Visit 2	Visit 3	Visit 4	Visit 5 (±Day 43)
		Day 1	±Day 2	±Day 15	±Day 29	
Informed Consent ¹	X					
Demographics	X					
Medical/Smoking History	X					
Inclusion/Exclusion Criteria	X					
Physical Examination including Height/Weight ²	X	X				X
Patency of nares	X	X		X	X	X
Pregnancy Test (urine; women of childbearing potential only) ³	X	X			X	X
LTOT on Subject's Usual Cannula	X	X				X
LTOT on INOpulse Specific Cannula		X		X	X	
Electrocardiogram	X ⁷				X ¹²	
Vital Signs and SpO ₂ ⁴	X ⁷	X ^{10, 11}		X ¹²	X ^{13, 16}	X ⁷
ABG		X ^{10, 11}			X ¹²	X ⁷
MetHb (via pulse oximetry)		X ^{10, 11}		X ¹²	X ¹³	X ⁷
6MWD with Borg CR10 Fatigue and Dyspnea Scale, and SpO ₂		X ^{10, 11}		X ¹²	X ¹³	X ⁷
PRO		X ^{10, 11}	X	X ¹²	X ¹³	X ⁷
Spirometry	X ^{7, 8}	X ^{10, 11}			X ¹³	X ⁷
Diffusion Capacity	X ^{7, 8}					
Body Plethysmography	X ^{7, 8}					
eGFR _{MDRD} determination	X	X ¹⁷			X ¹⁷	
High Resolution Computed Tomography (HRCT) scan (for FRI) ⁵		X ^{10, 11}			X ¹²	
2-D Echocardiogram with Doppler	X ^{7, 9}				X ¹³	X ⁷

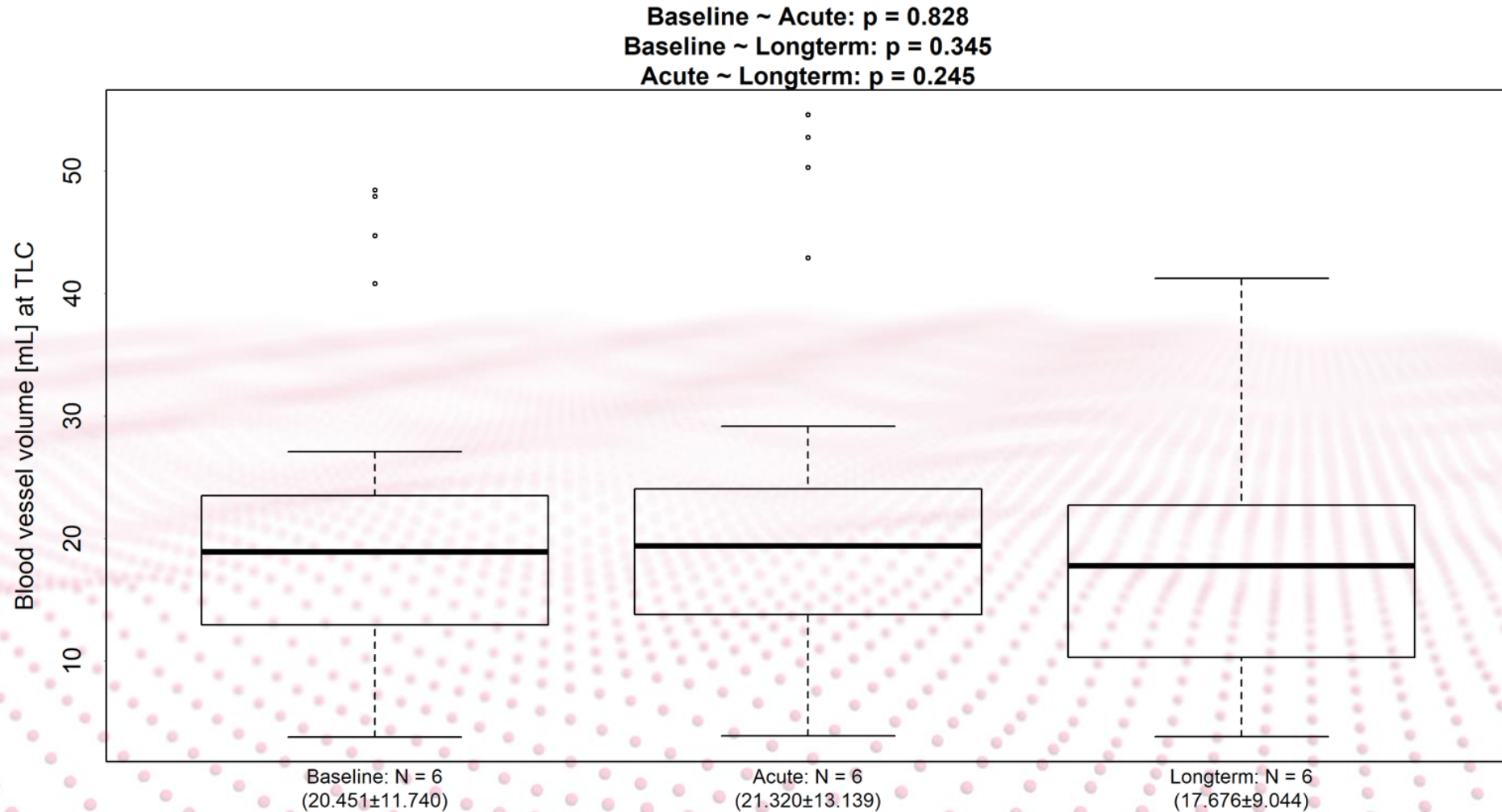
STUDY DESIGN



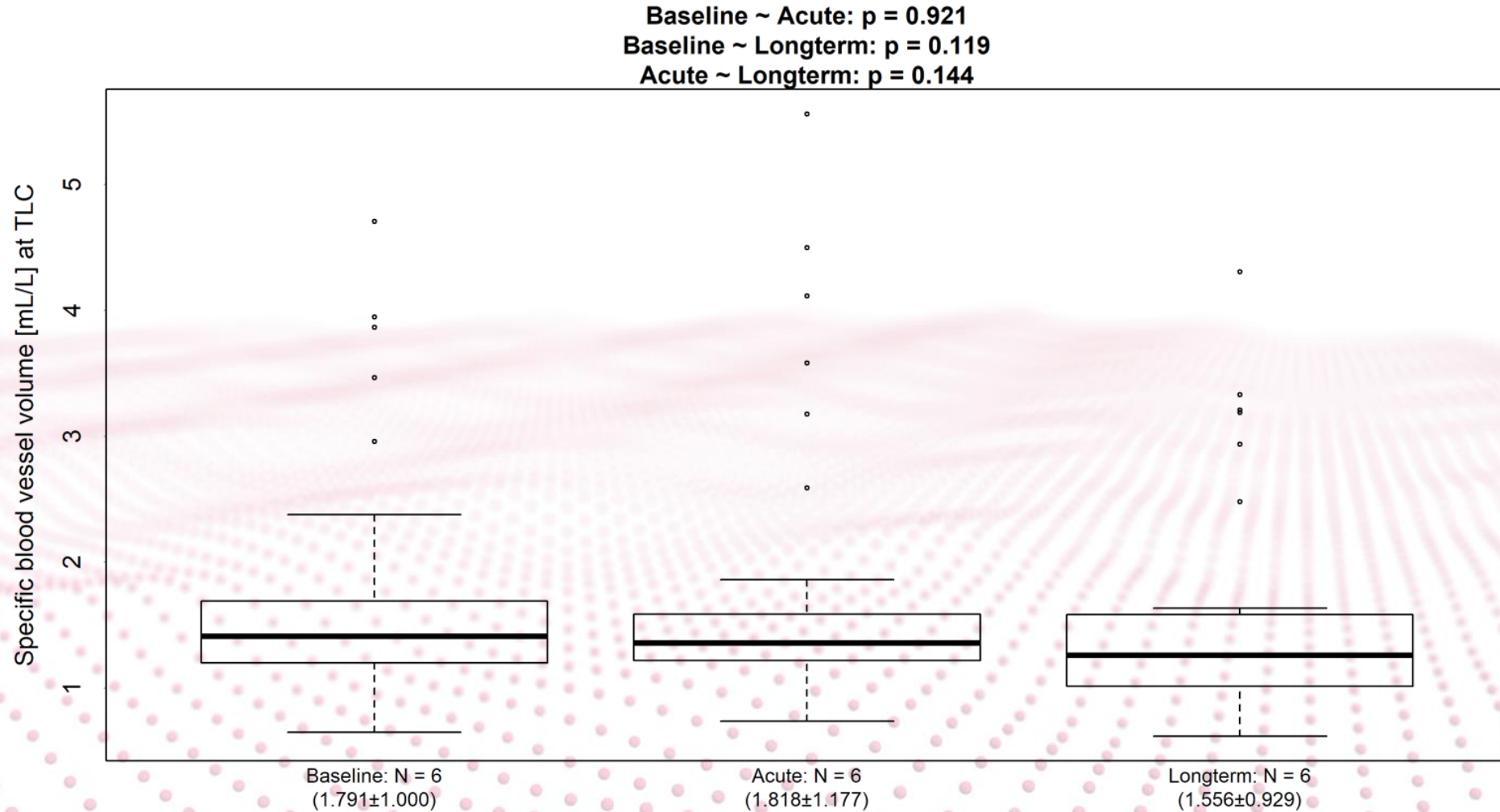
DEMOGRAPHICS

Characteristics		Unit
Age	64.60 ± 7.41	years
Sex	8M:2F	/
FEV1	1.35 ± 0.53	L
FEV1	43.85 ± 16.25	%pred
FVC	3.30 ± 0.59	L
FVC	84.34 ± 11.37	%pred
FEF 25-75%	0.44 ± 0.27	L
FEF 25-75%	13.89 ± 9.87	%pred
RV	4.30 ± 1.27	L
FRC	5.59 ± 1.33	L
TCO	2.87 ± 1.05	mmol/min.kPa
VA	1.57 ± 1.13	L
LTOT	2.65 ± 3.15	L/min
Hours	20.10 ± 3.48	hours
spO2	94.0 ± 2.86	%
sPAP	58.1 ± 16.31	mmHG
Heart rate	85.0 ± 16.87	bpm
Systolic BP	129.60 ± 25.05	mmHg
Diastolic BP	75.60 ± 12.13	mmHg

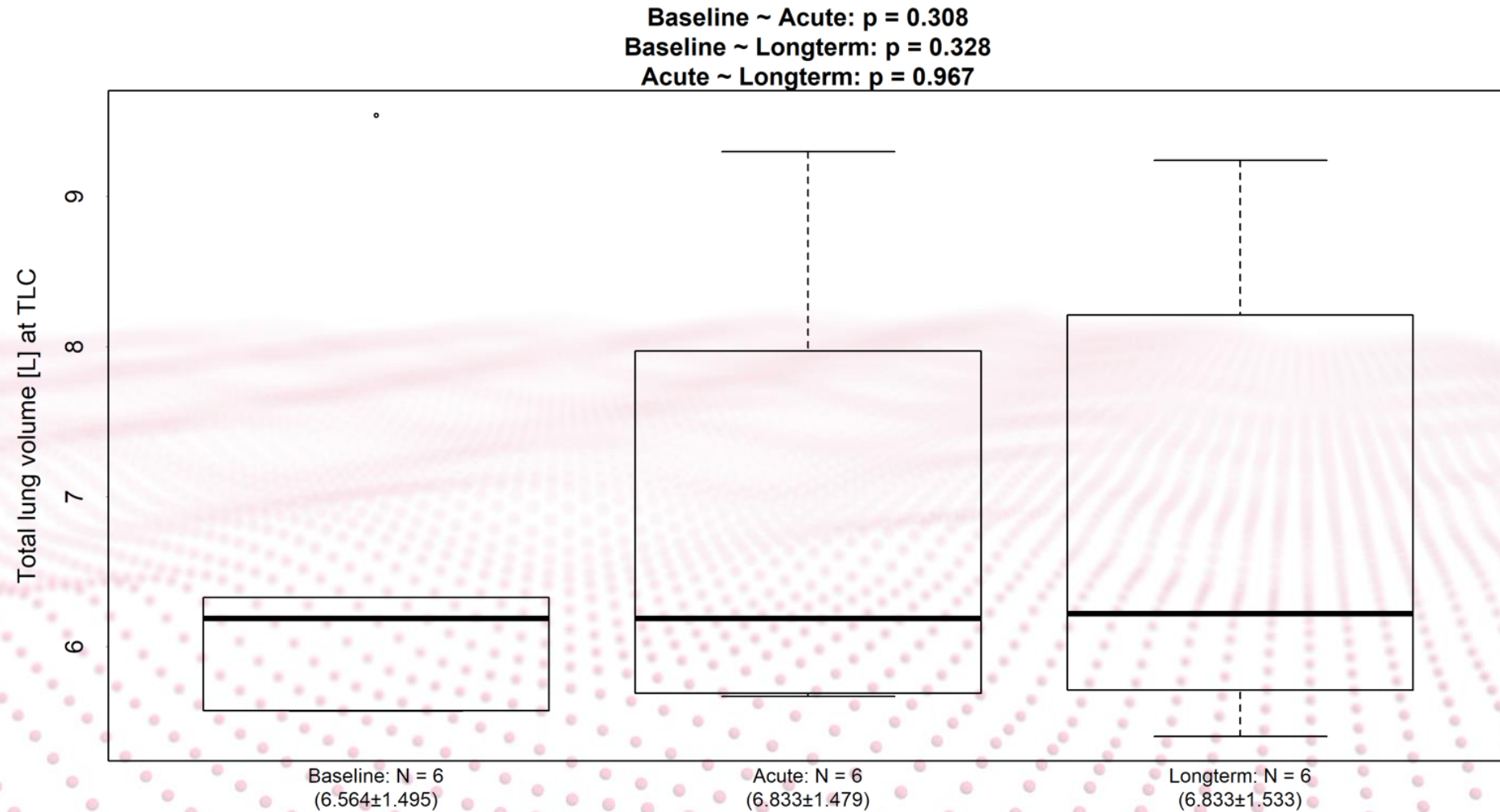
FRI RESULTS – Segmented Blood vessel volume



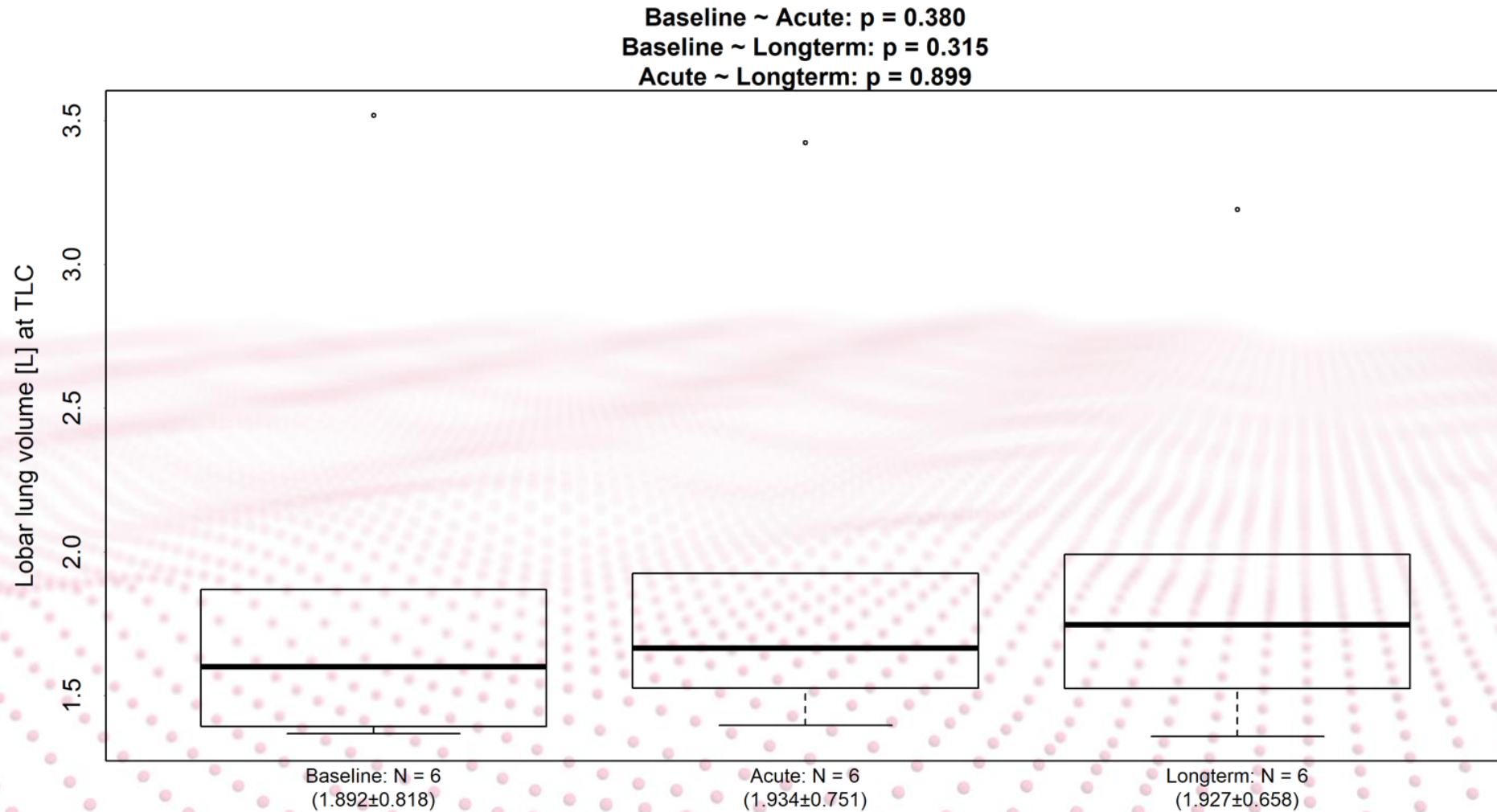
FRI RESULTS – Segmented Specific blood vessel volume



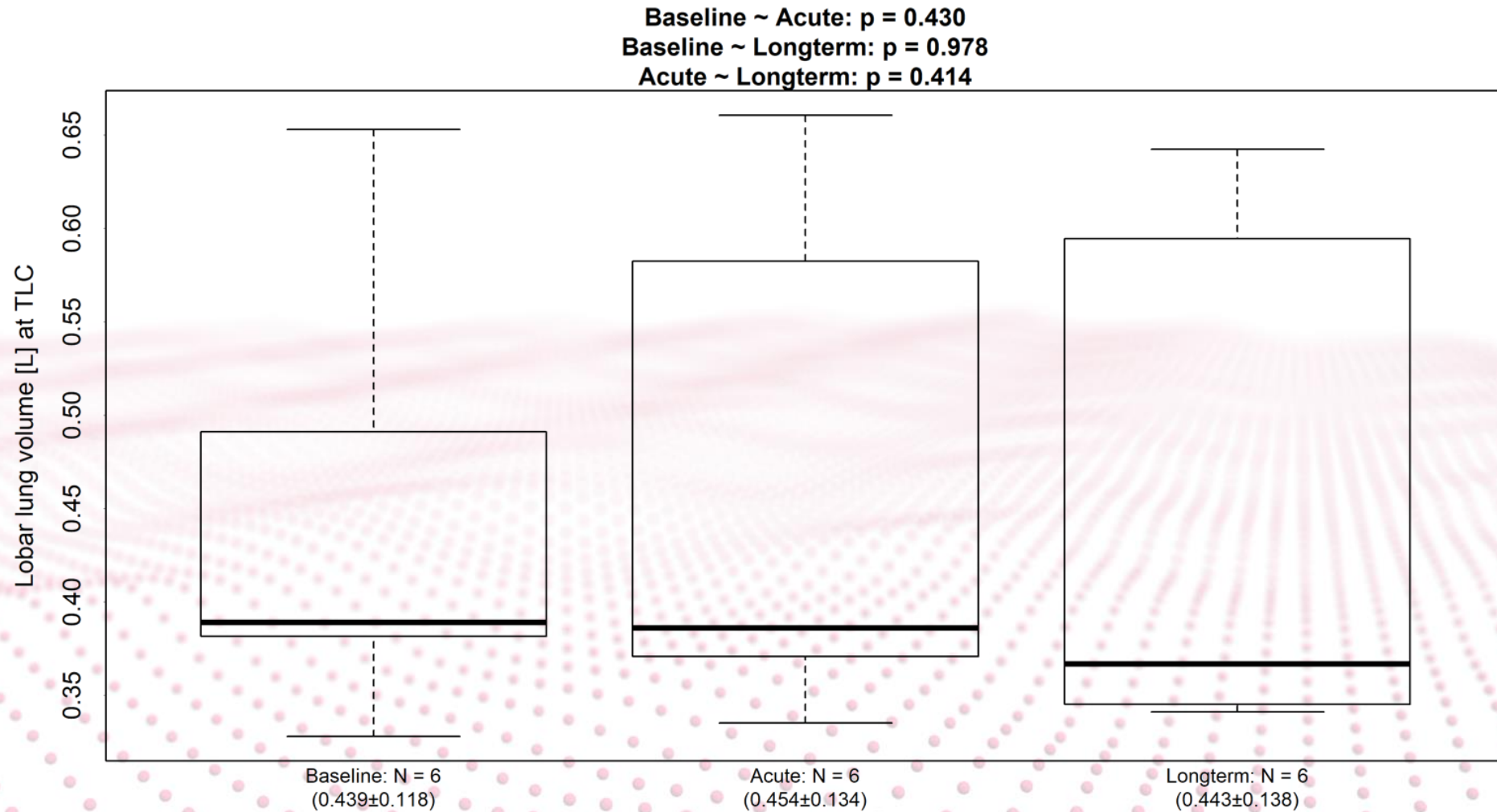
FRI RESULTS – Total lung volume



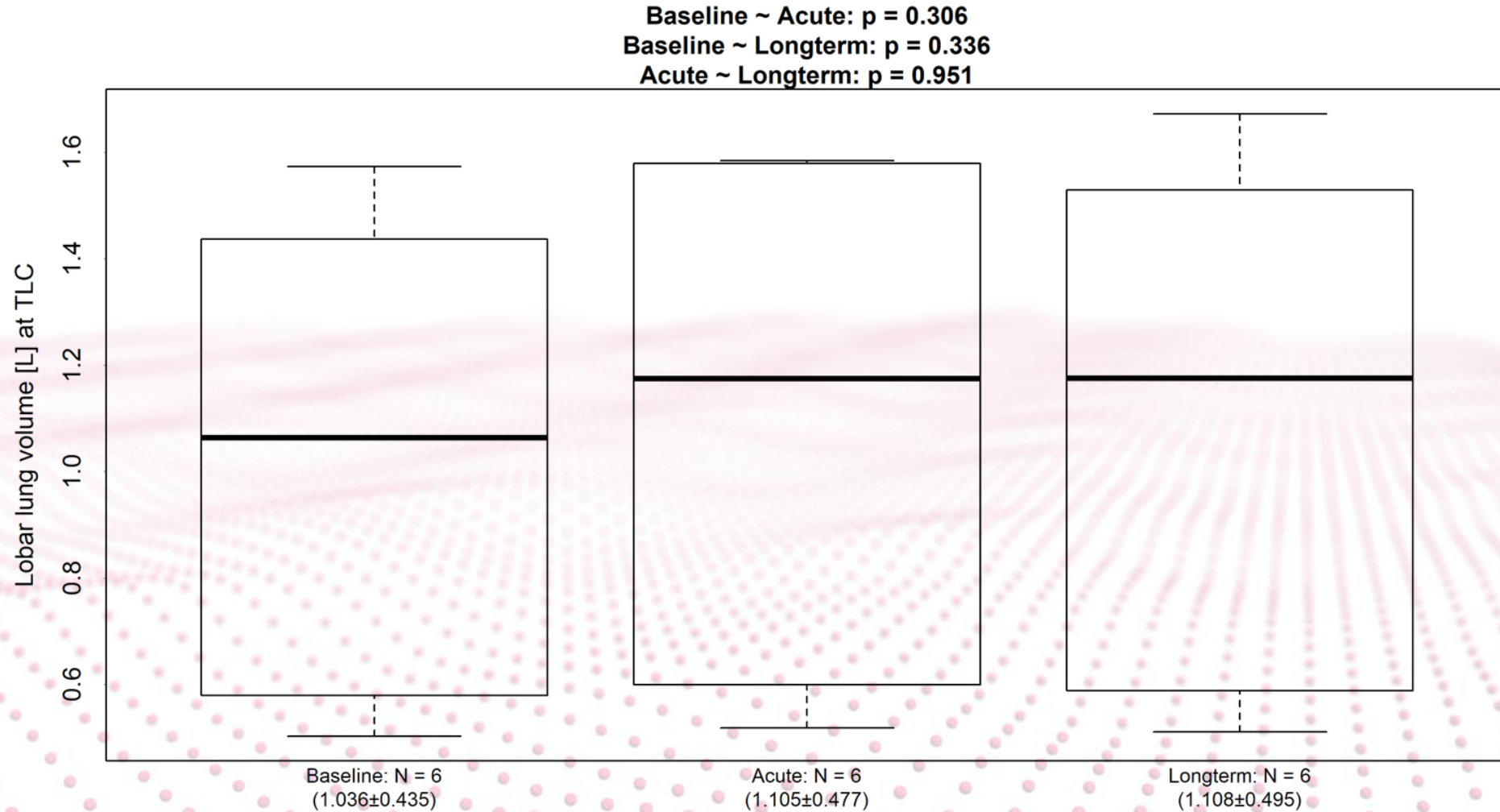
FRI RESULTS – RUL volume



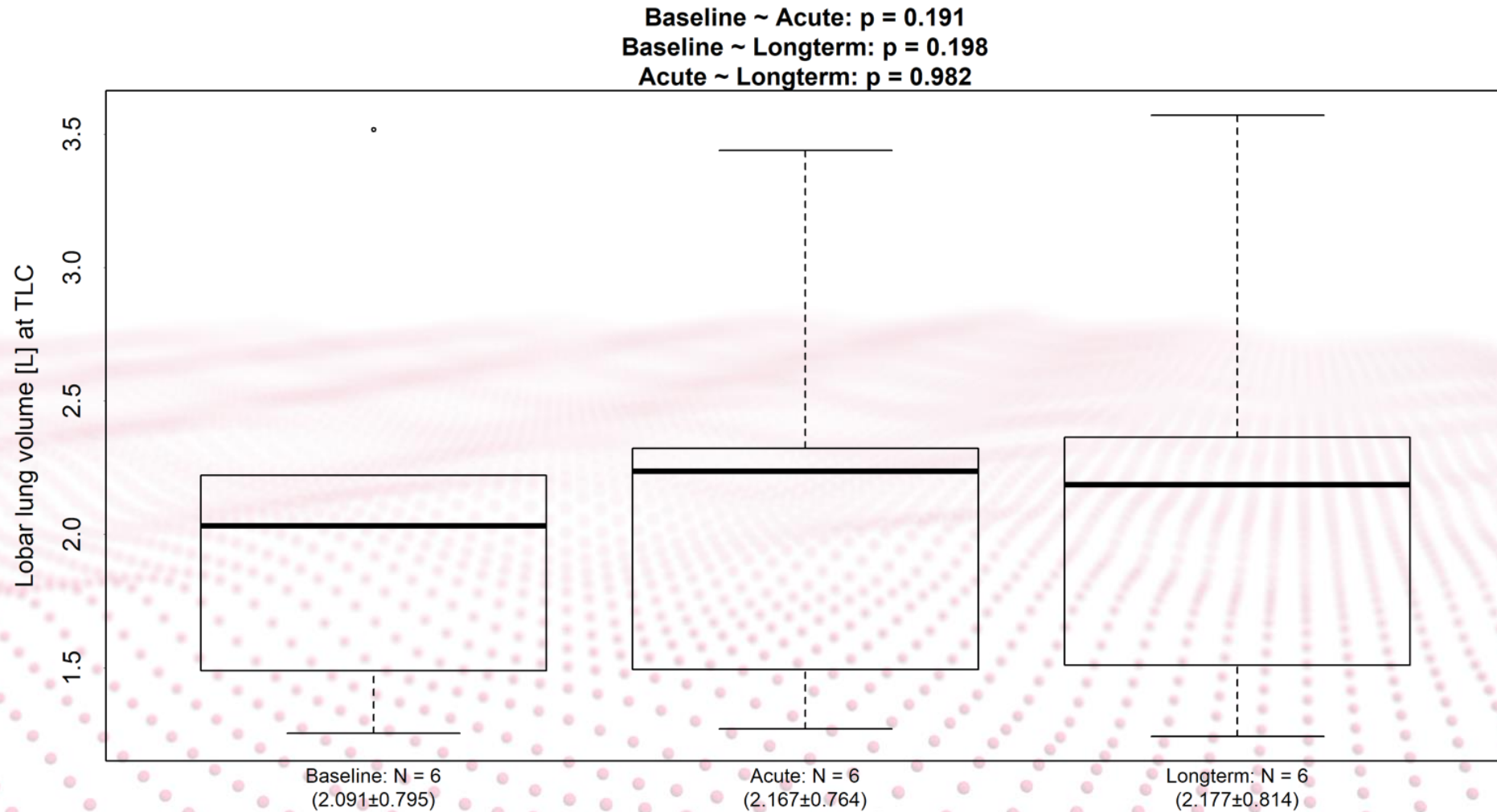
FRI RESULTS – RML volume



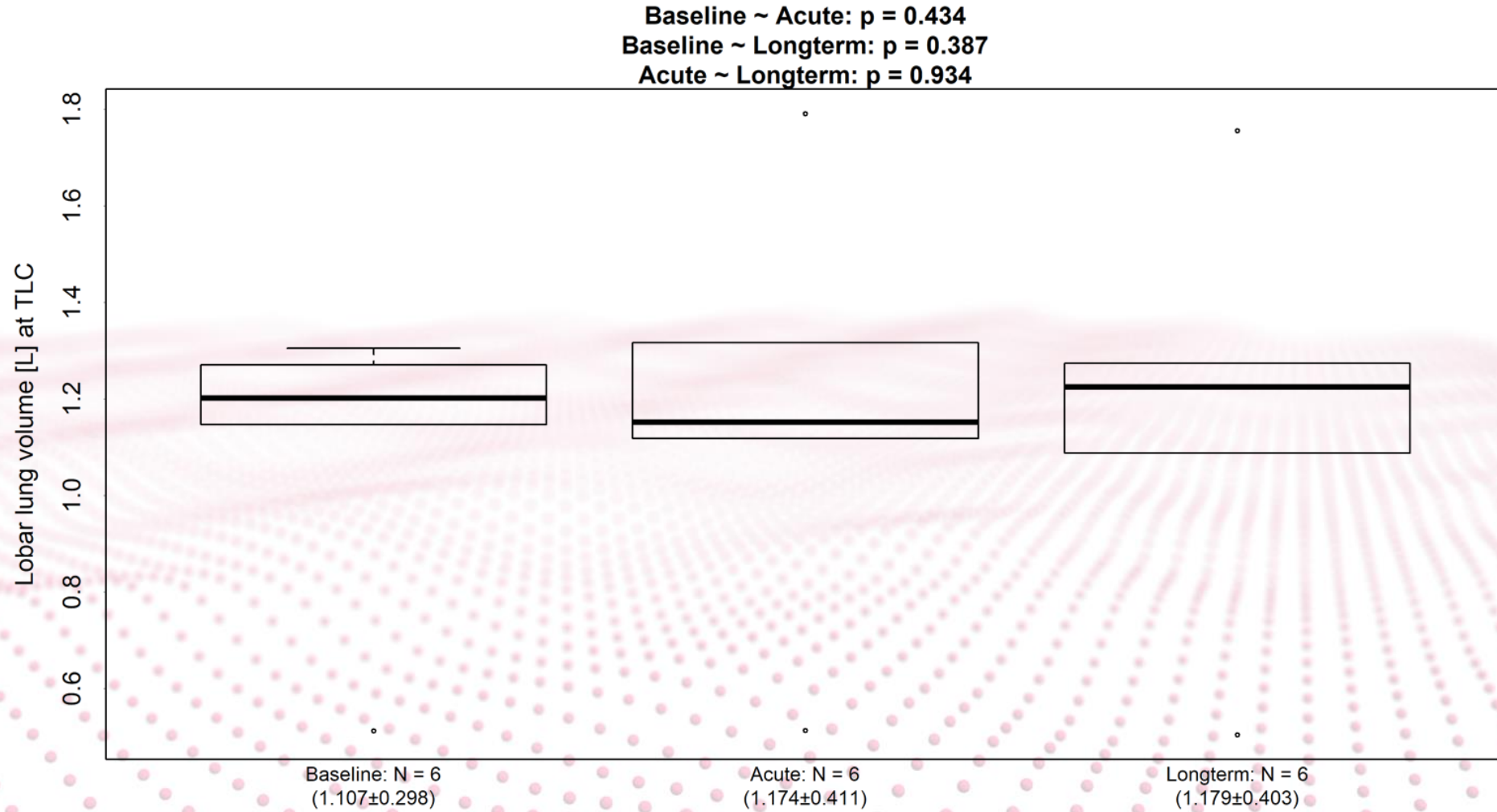
FRI RESULTS – RLL volume



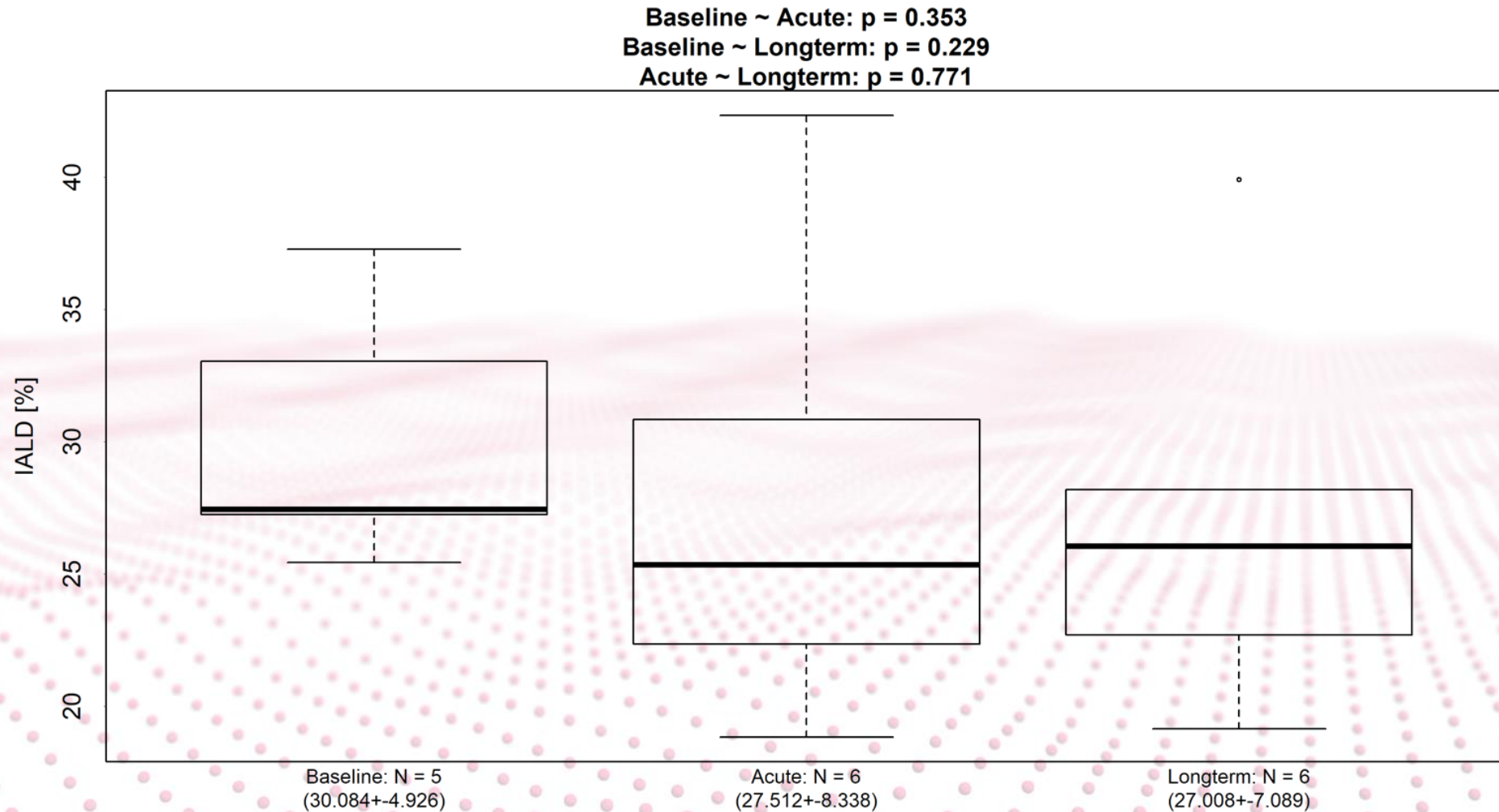
FRI RESULTS – LUL volume



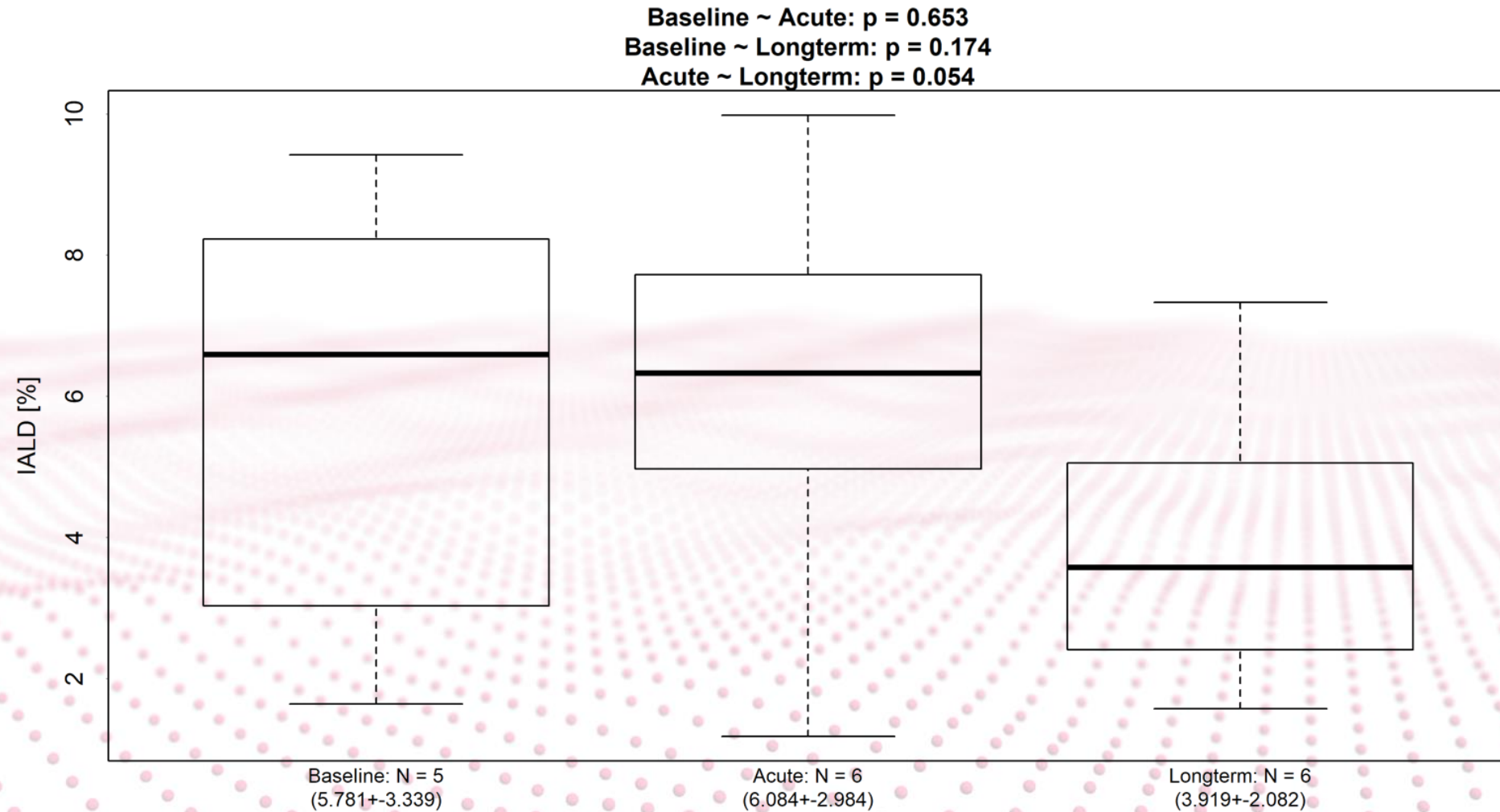
FRI RESULTS – LLL volume



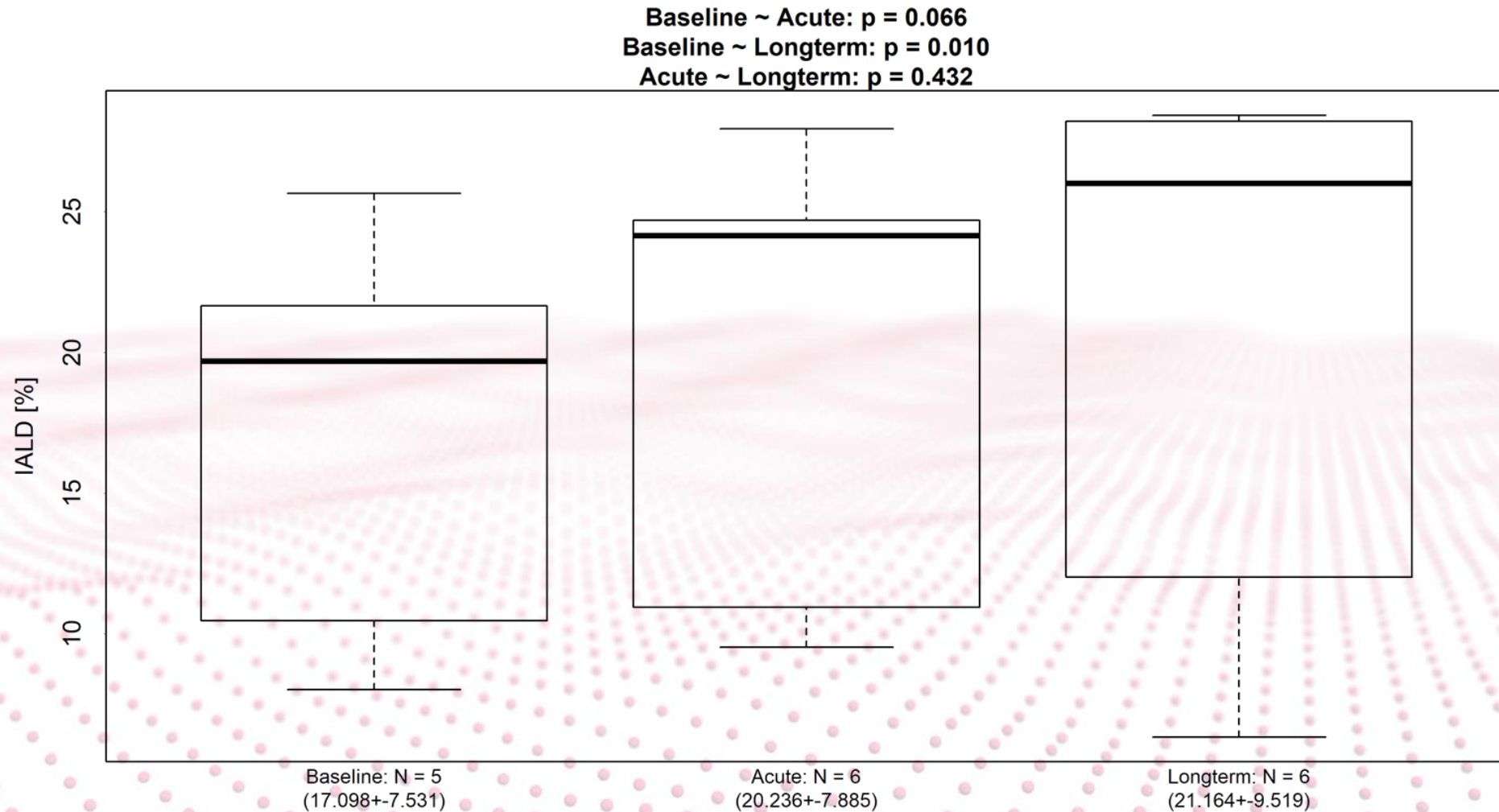
FRI RESULTS – Internal airflow distribution RUL



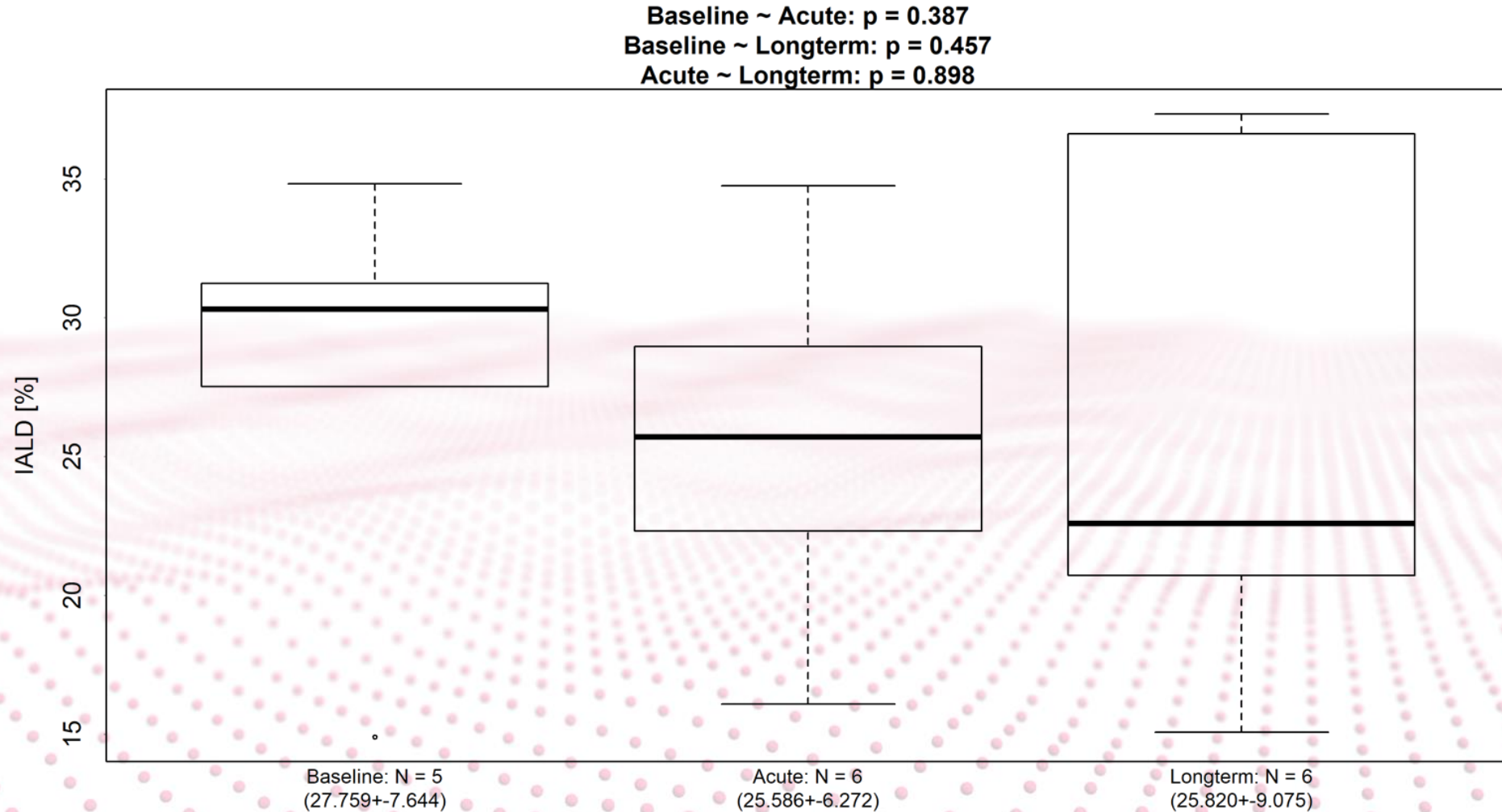
FRI RESULTS – Internal airflow distribution RML



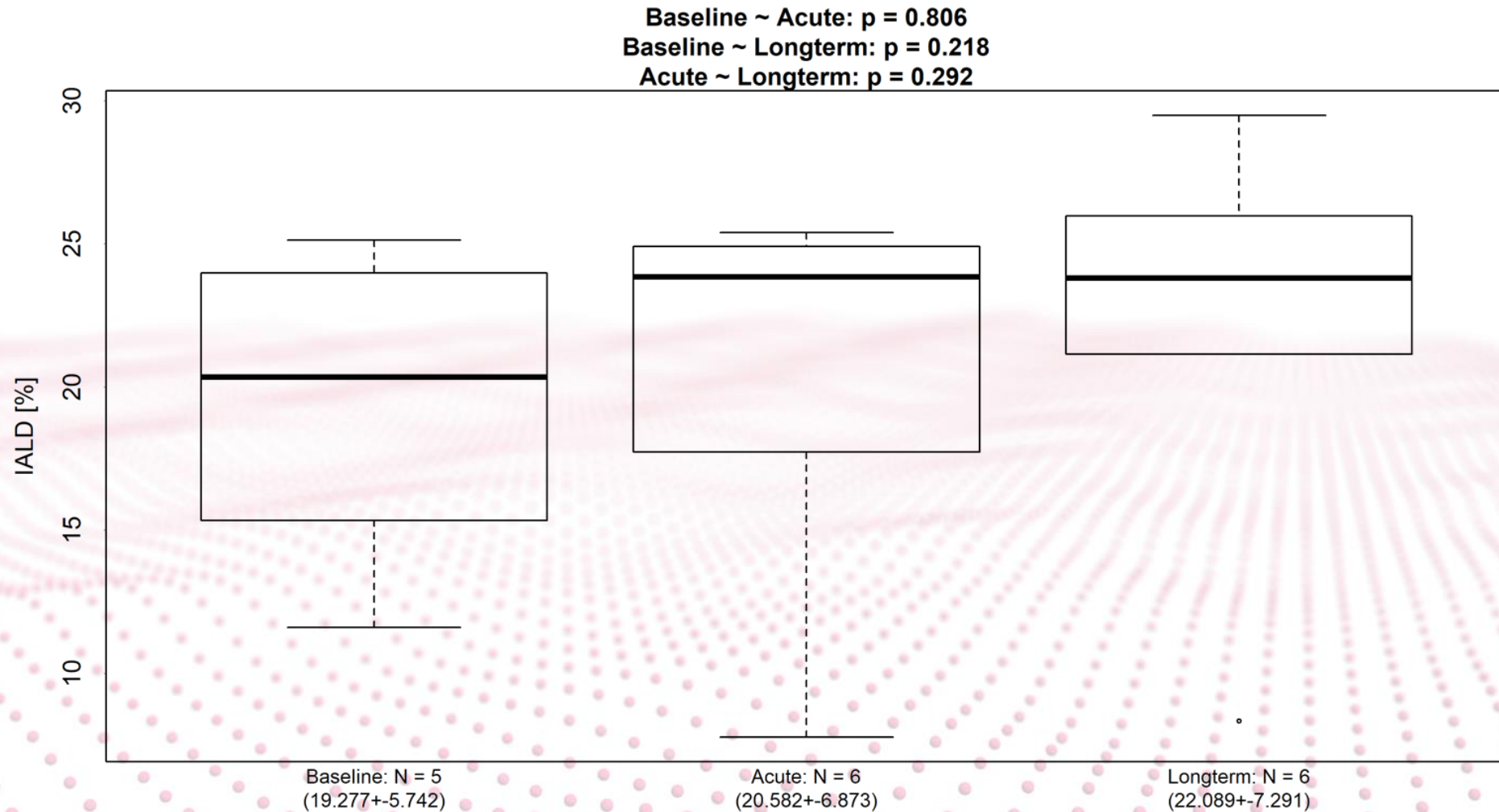
FRI RESULTS – Internal airflow distribution RLL



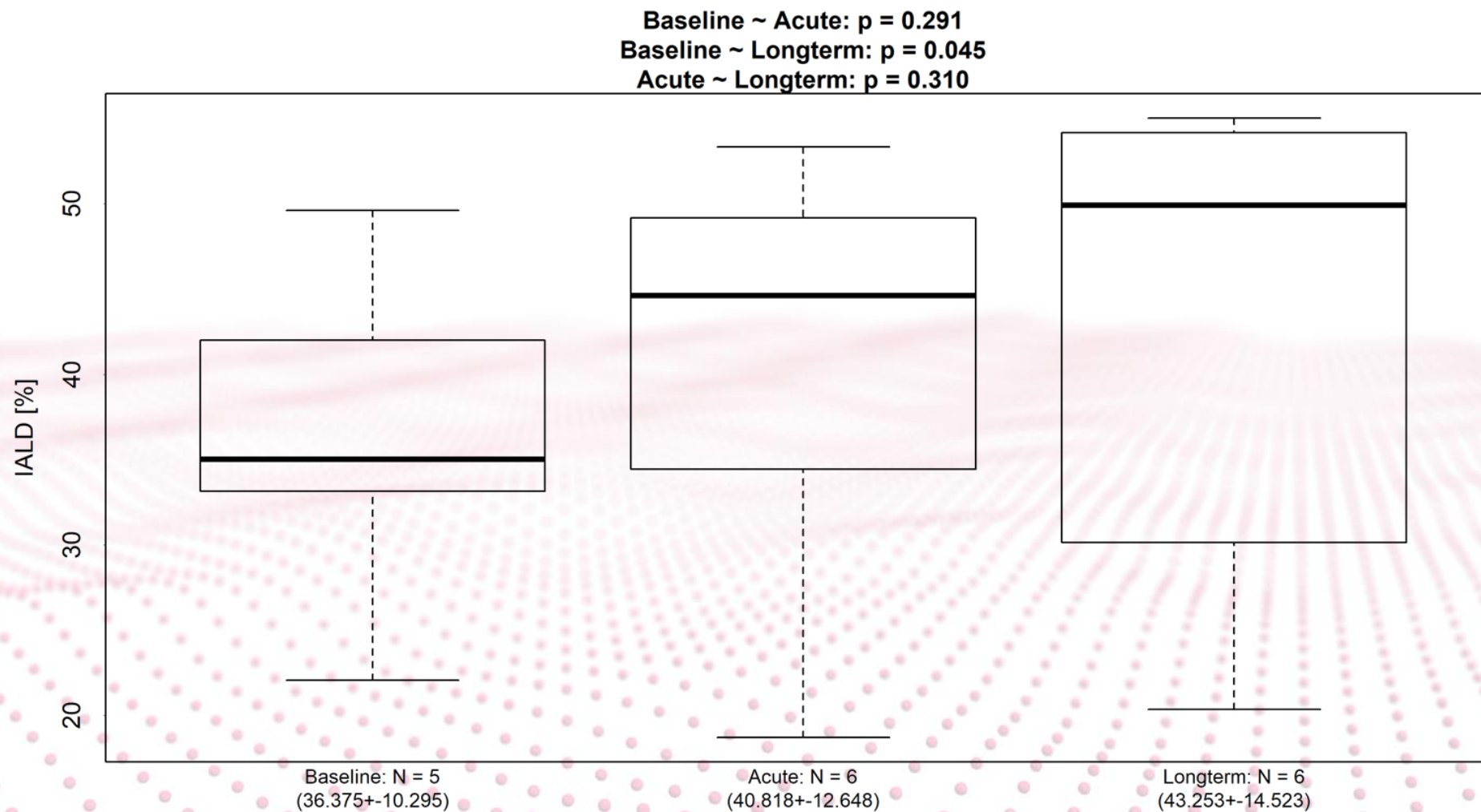
FRI RESULTS – Internal airflow distribution LUL



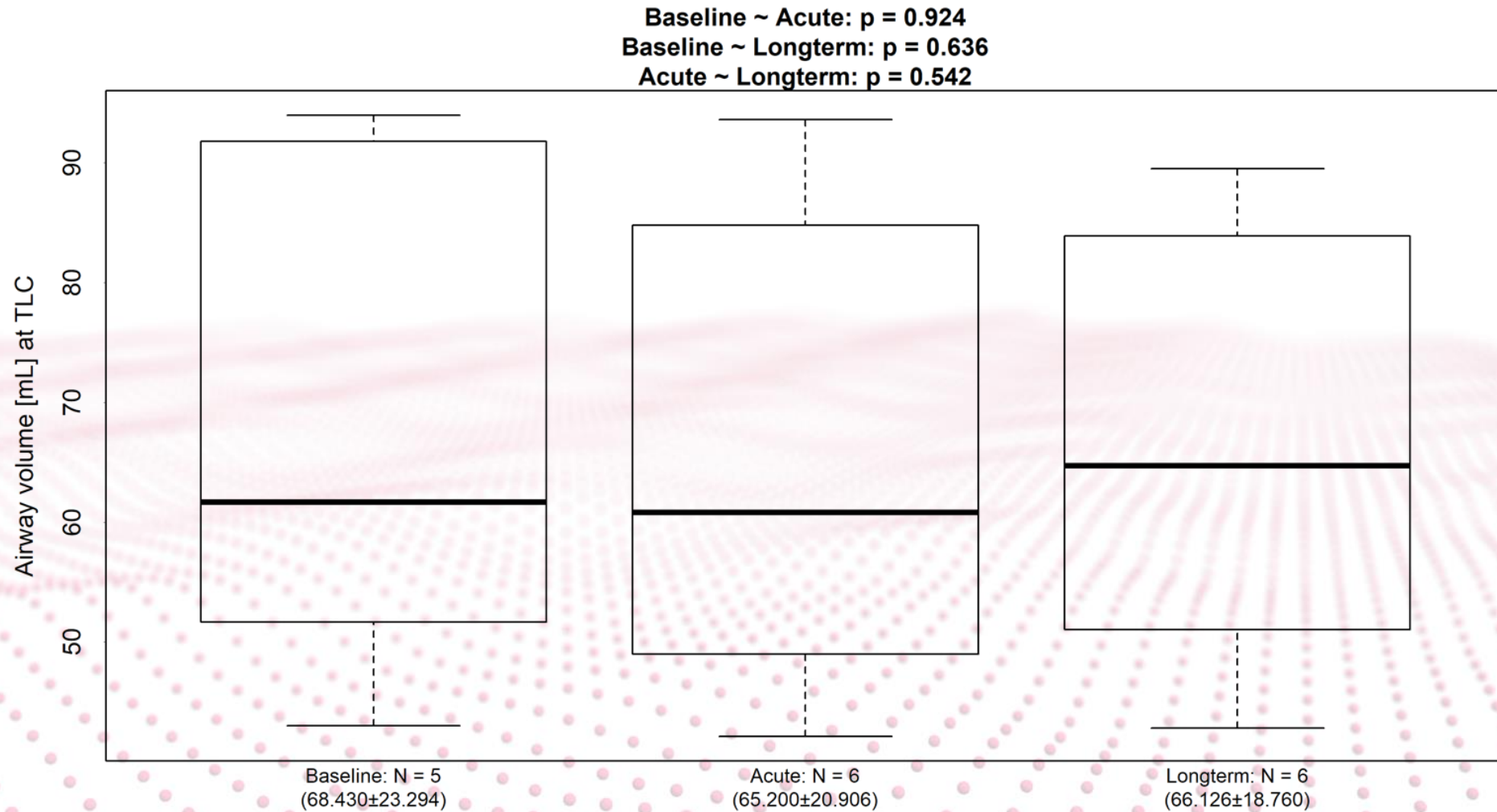
FRI RESULTS – Internal airflow distribution LLL



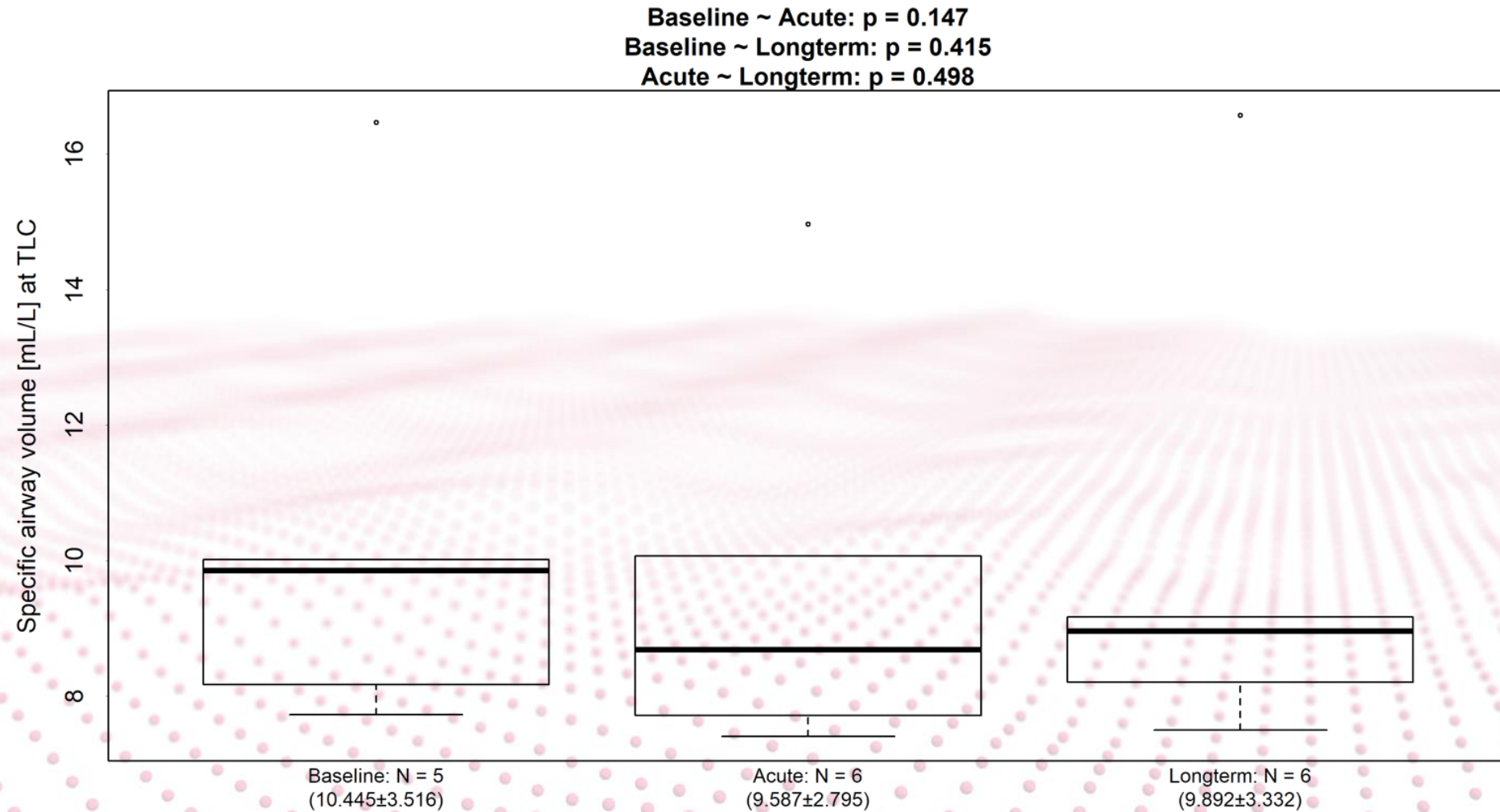
FRI RESULTS – Internal airflow distribution RLL/LLL



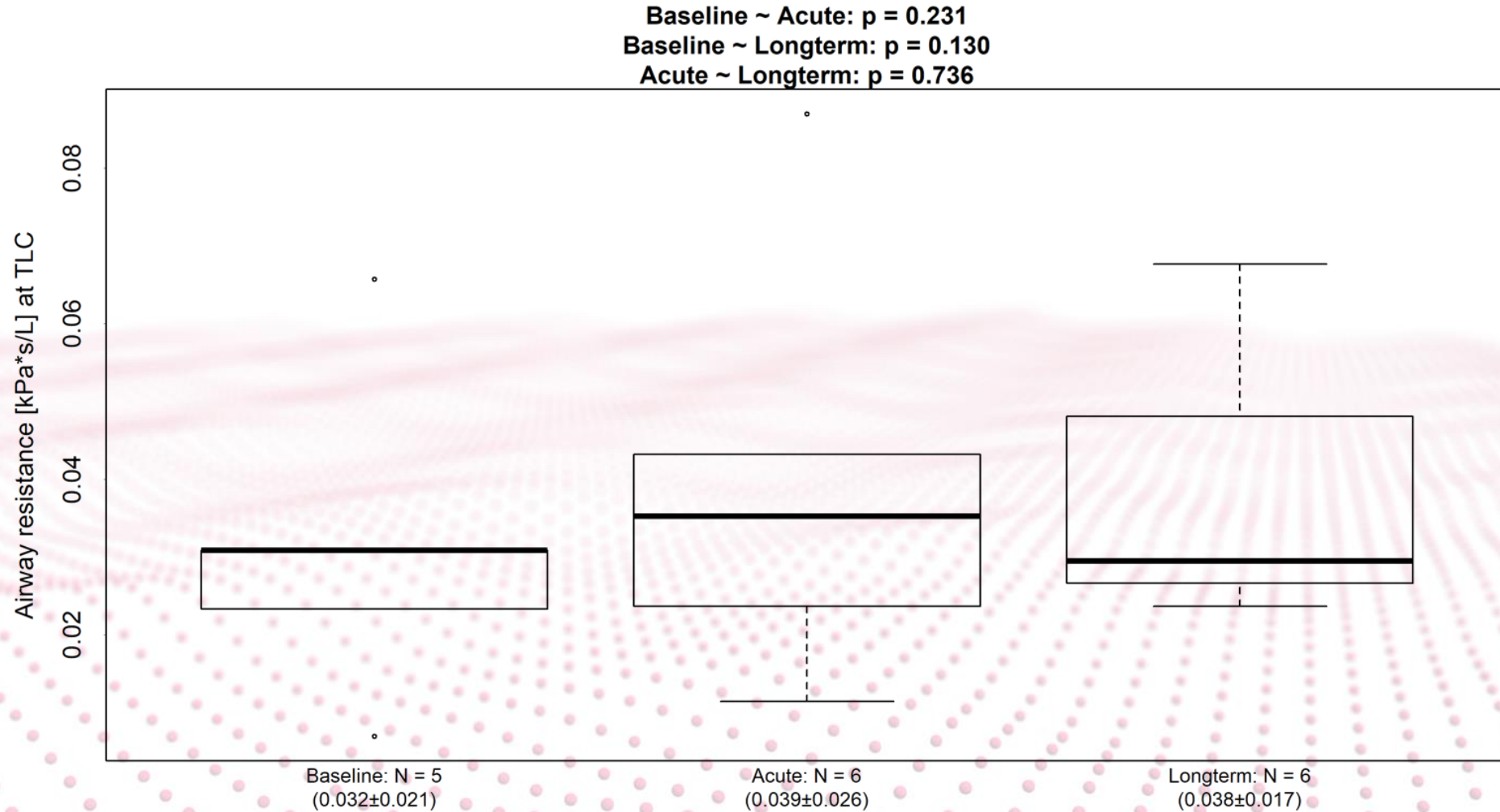
FRI RESULTS – Airway volume



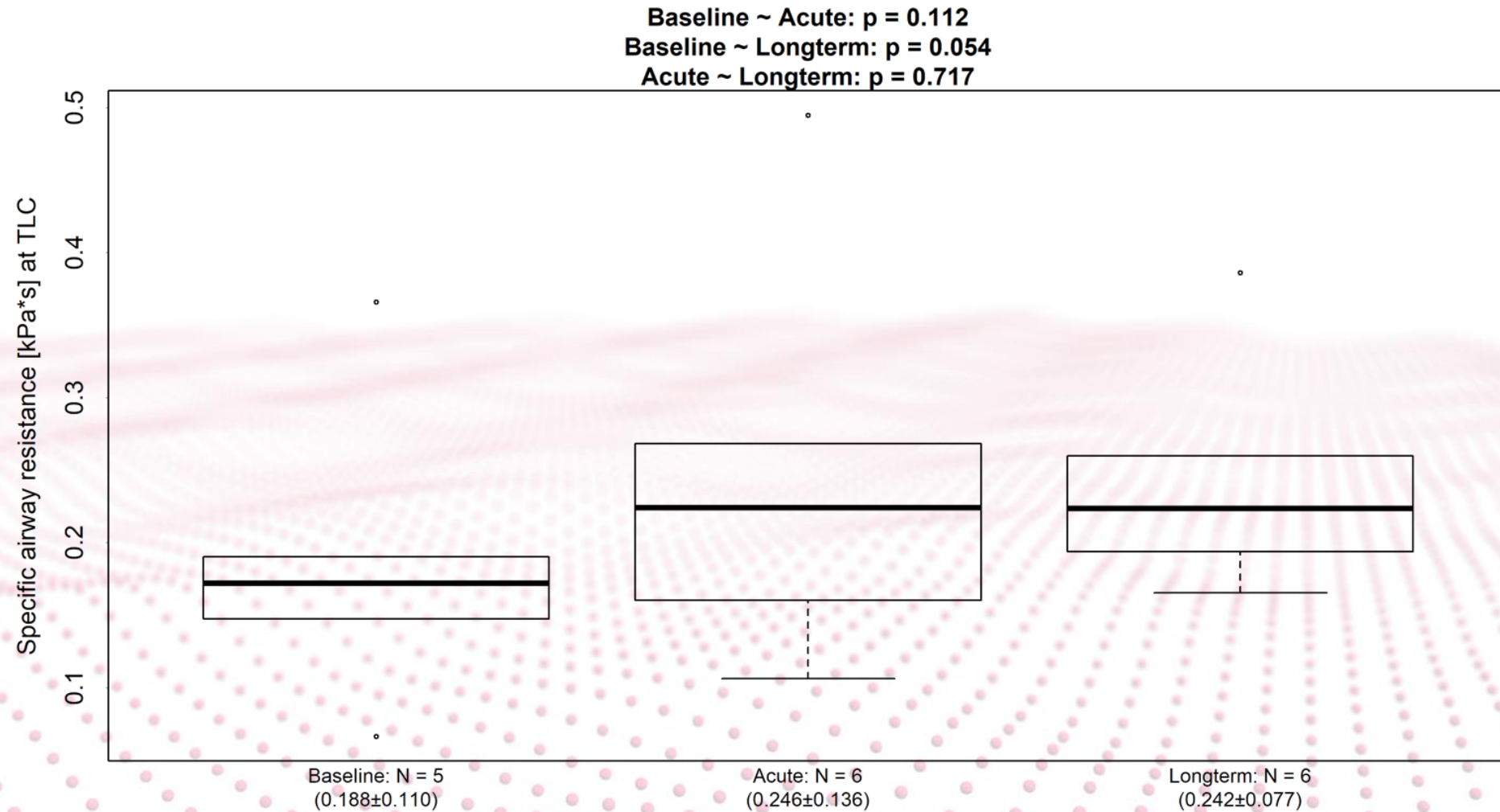
FRI RESULTS – Specific airway volume



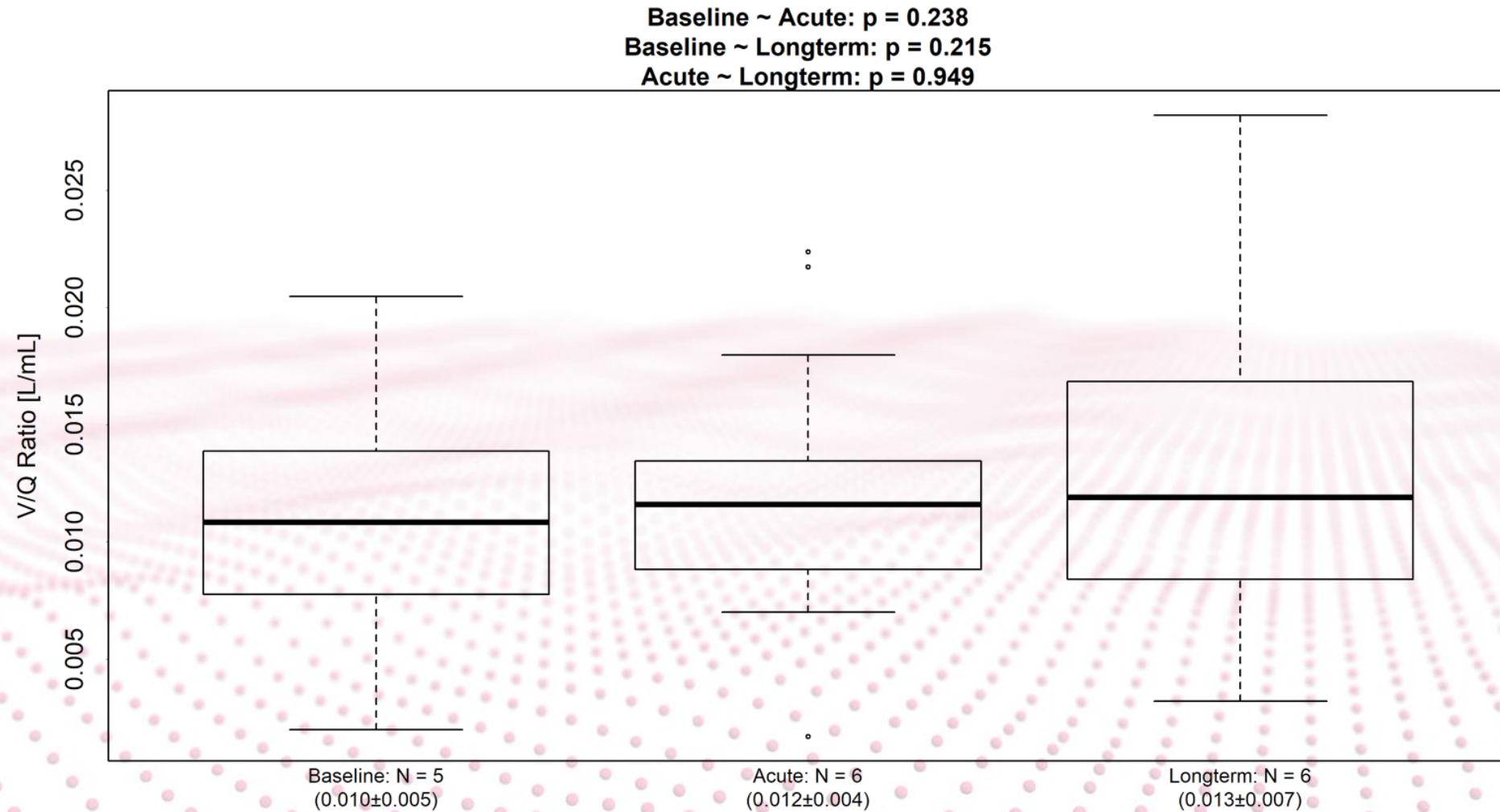
FRI RESULTS – Airway resistance



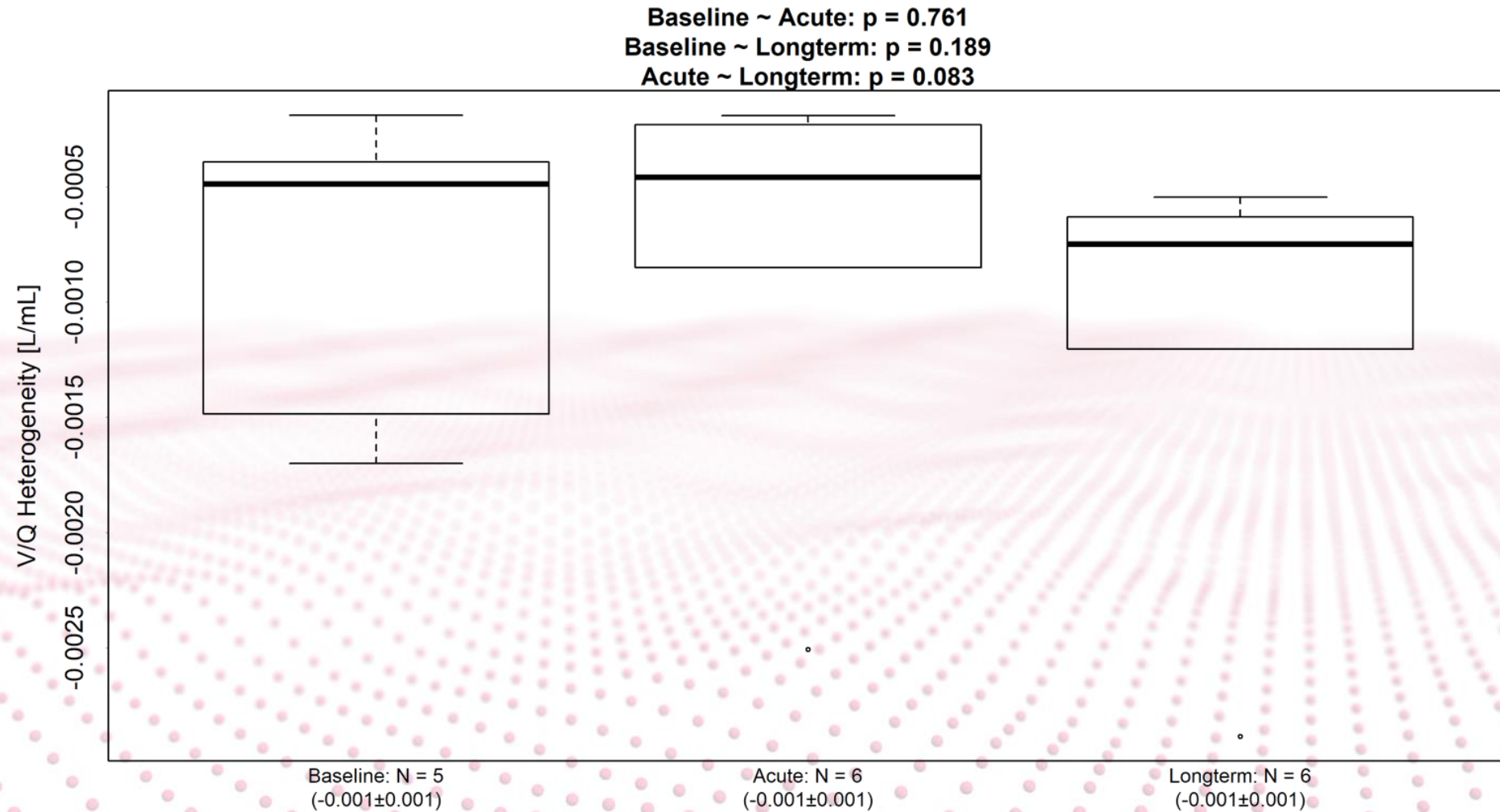
FRI RESULTS – Specific airway resistance



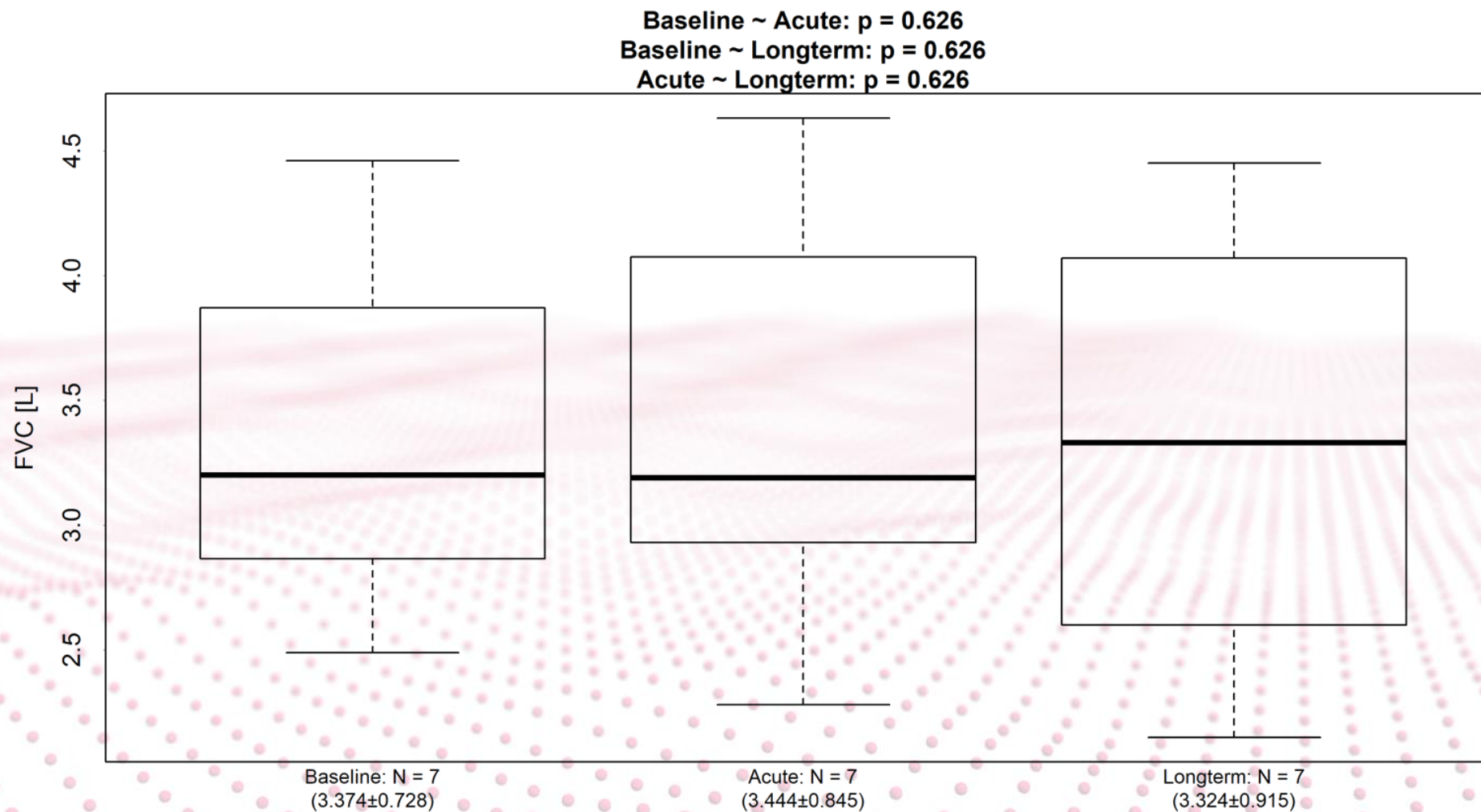
FRI RESULTS – Ventilation/Perfusion



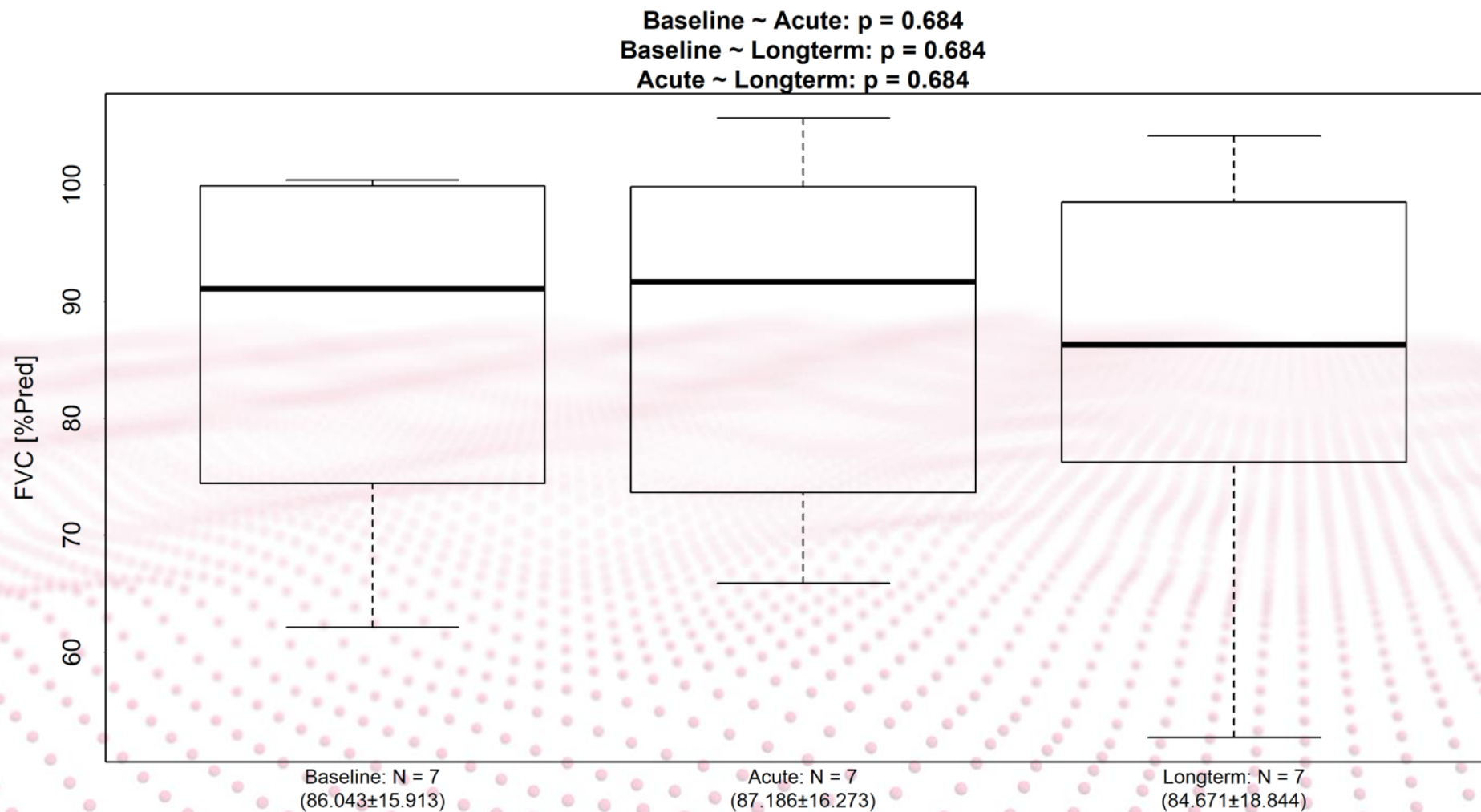
FRI RESULTS – Ventilation/Perfusion heterogeneity



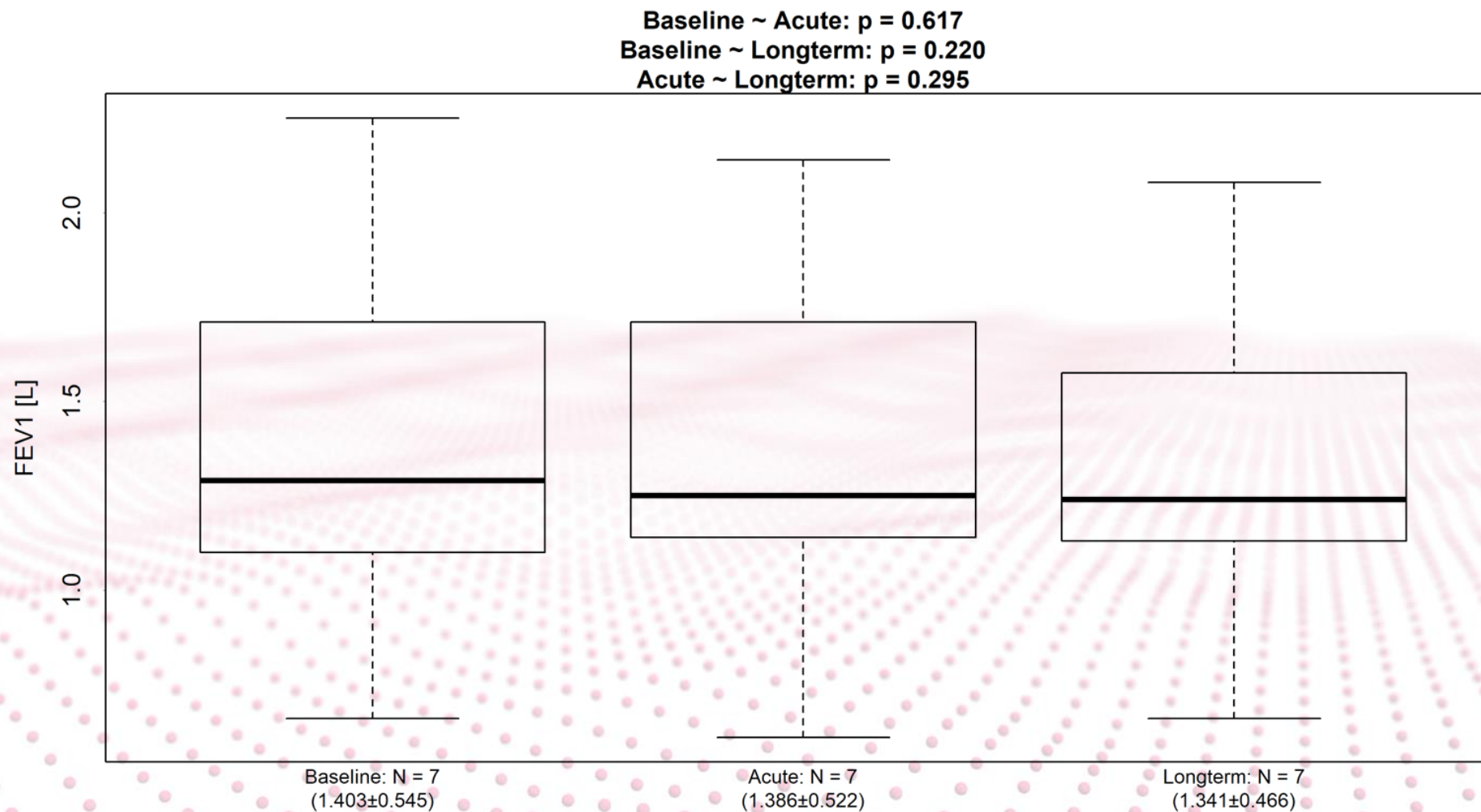
CLINICAL RESULTS – FVC



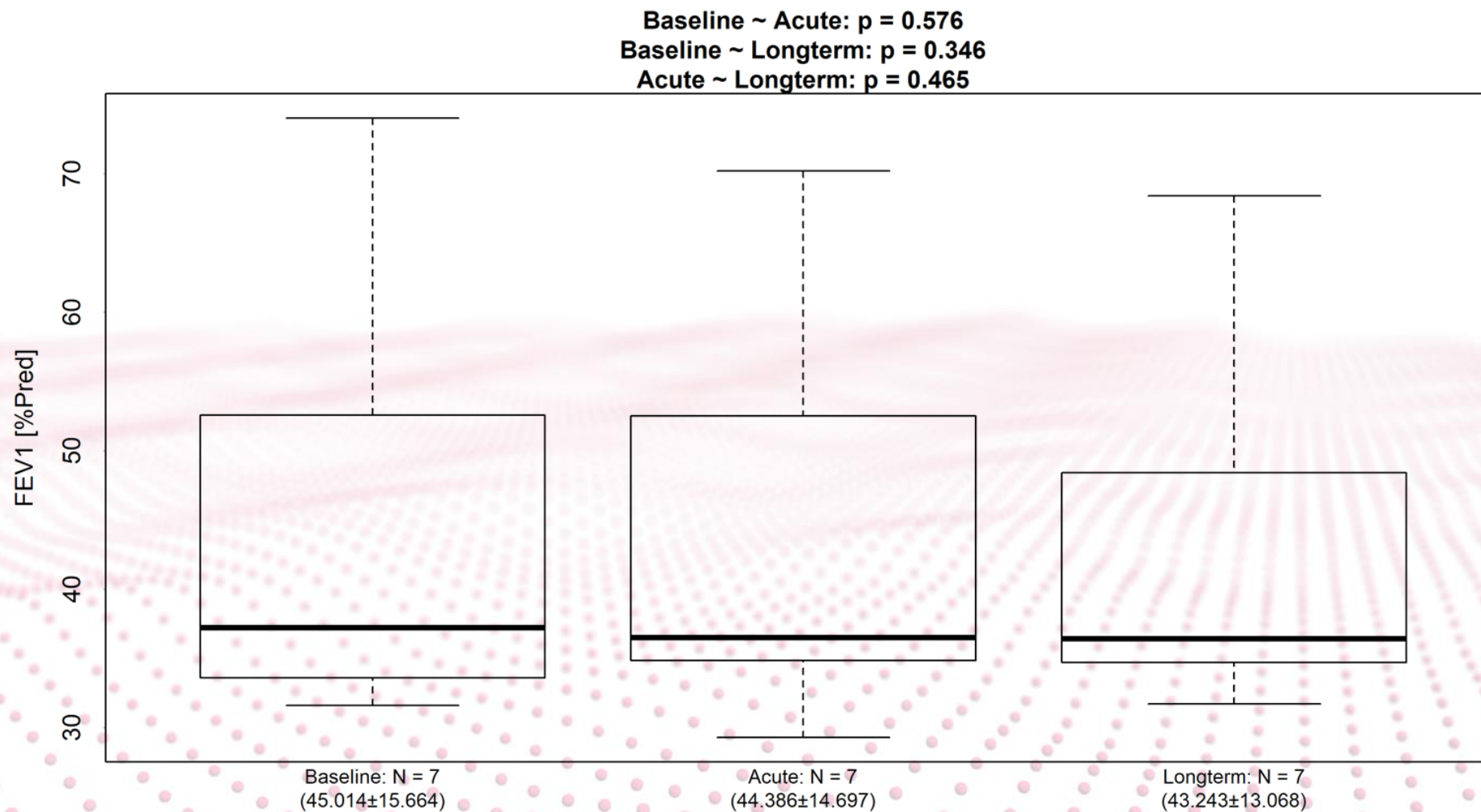
CLINICAL RESULTS – FVC



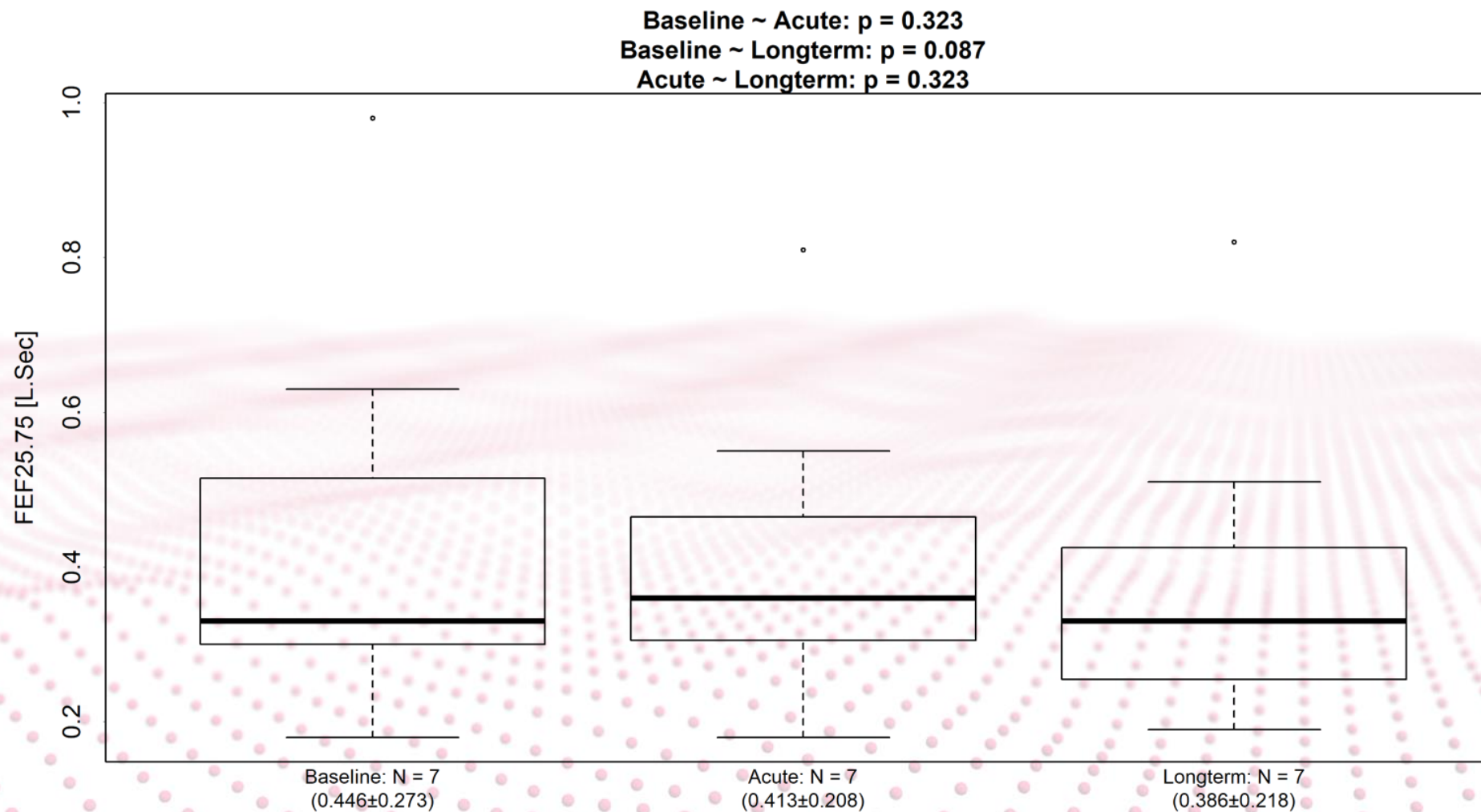
CLINICAL RESULTS – FEV1



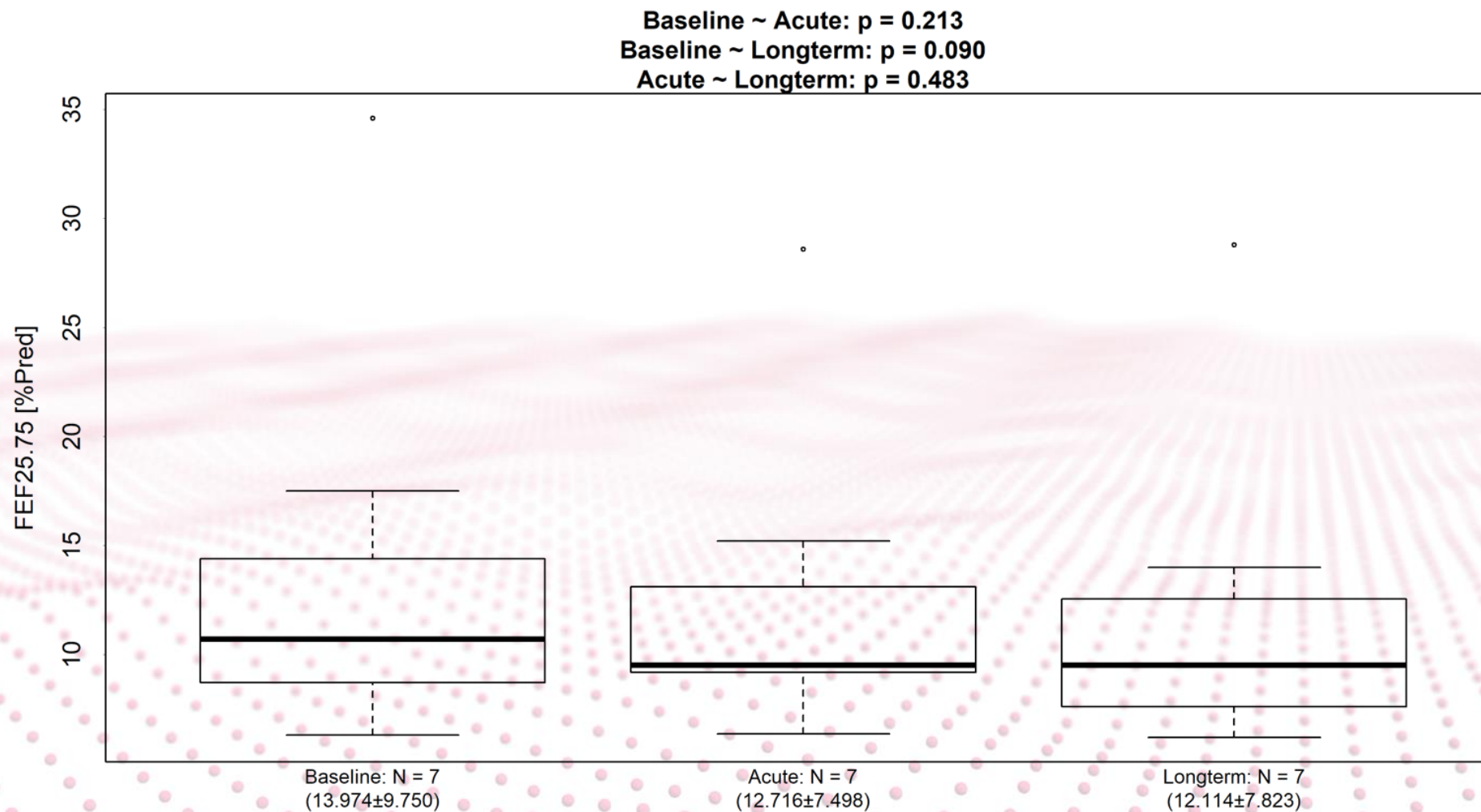
CLINICAL RESULTS – FEV1



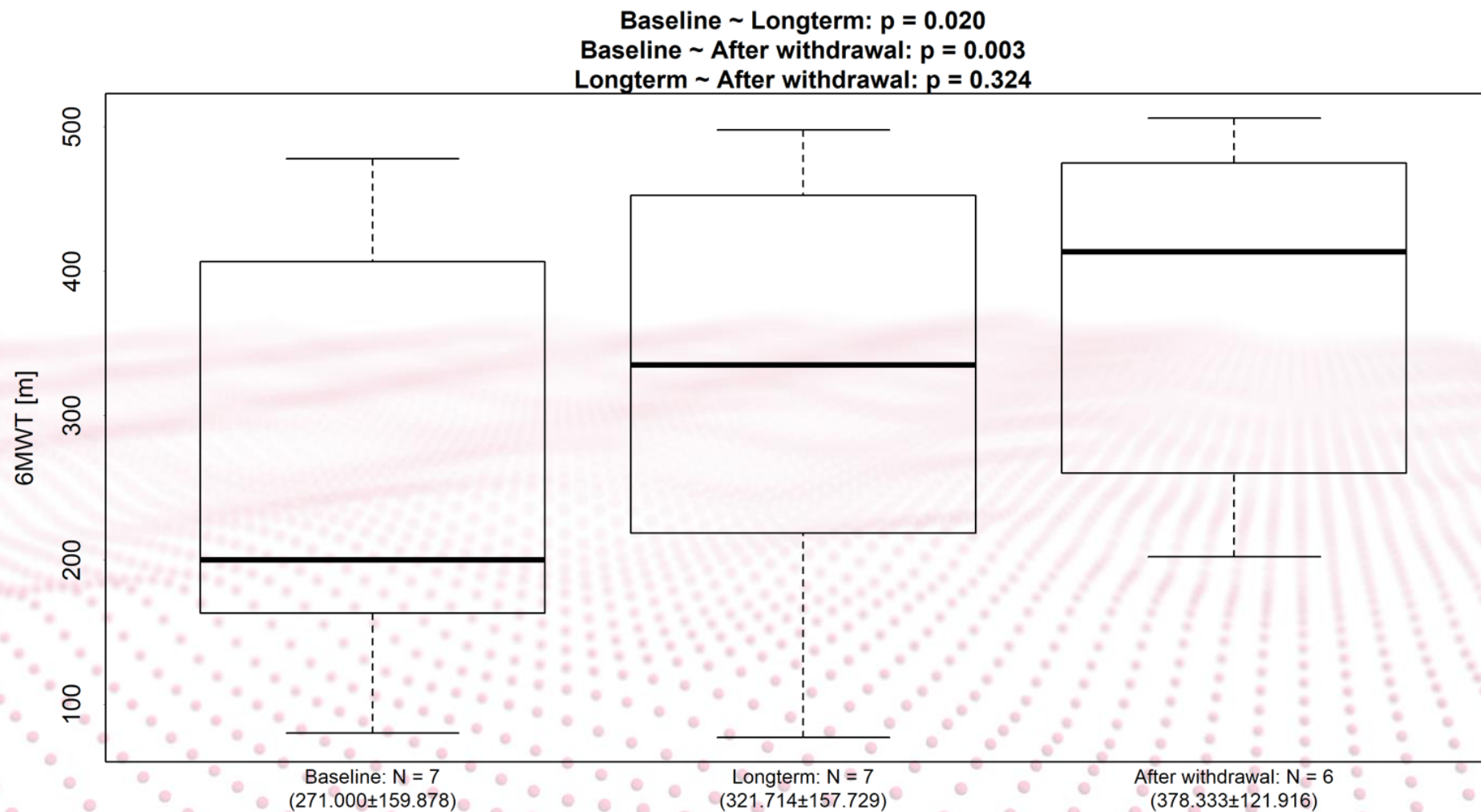
CLINICAL RESULTS – FEF 25-75



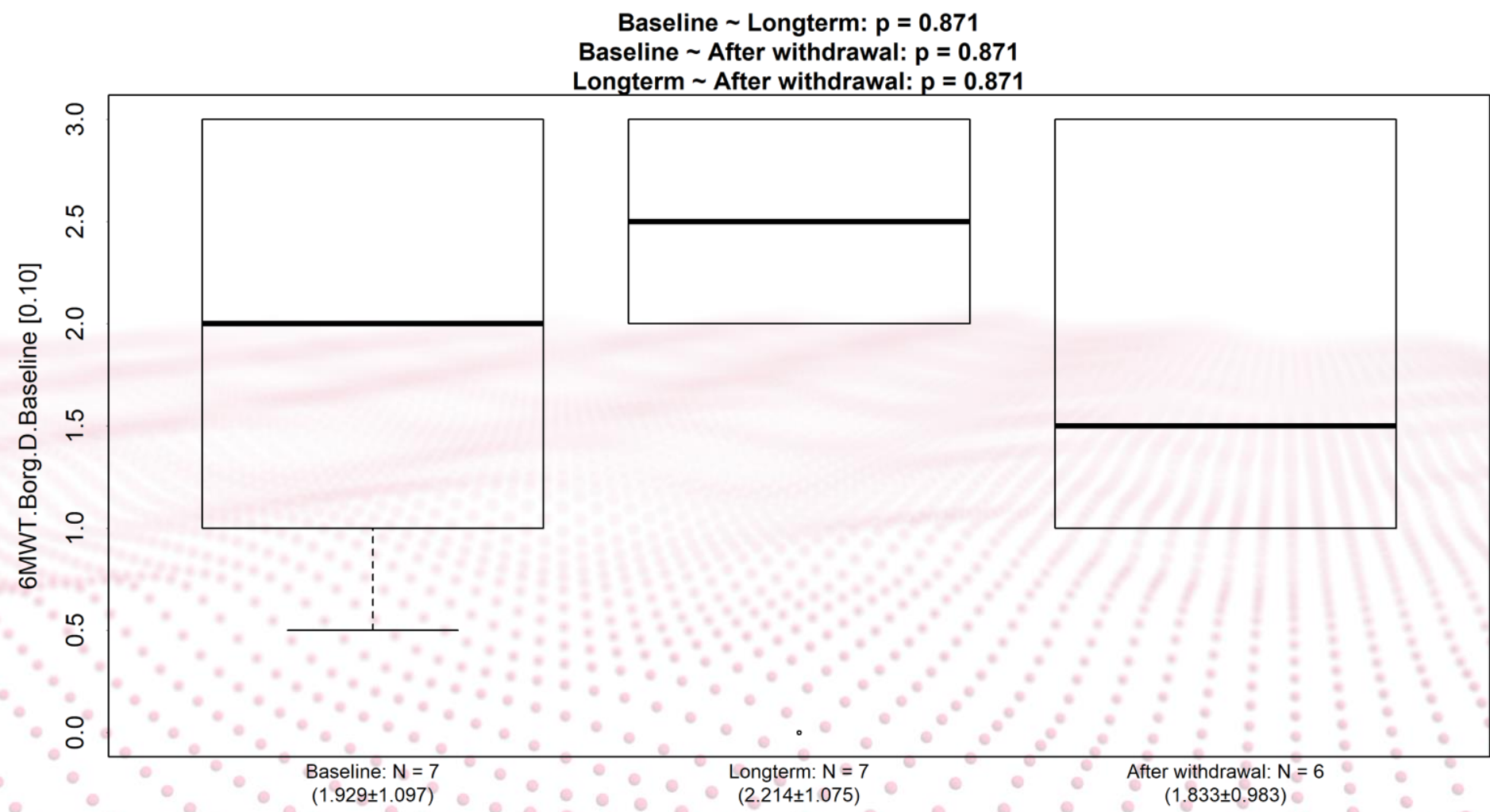
CLINICAL RESULTS – FEF 25-75



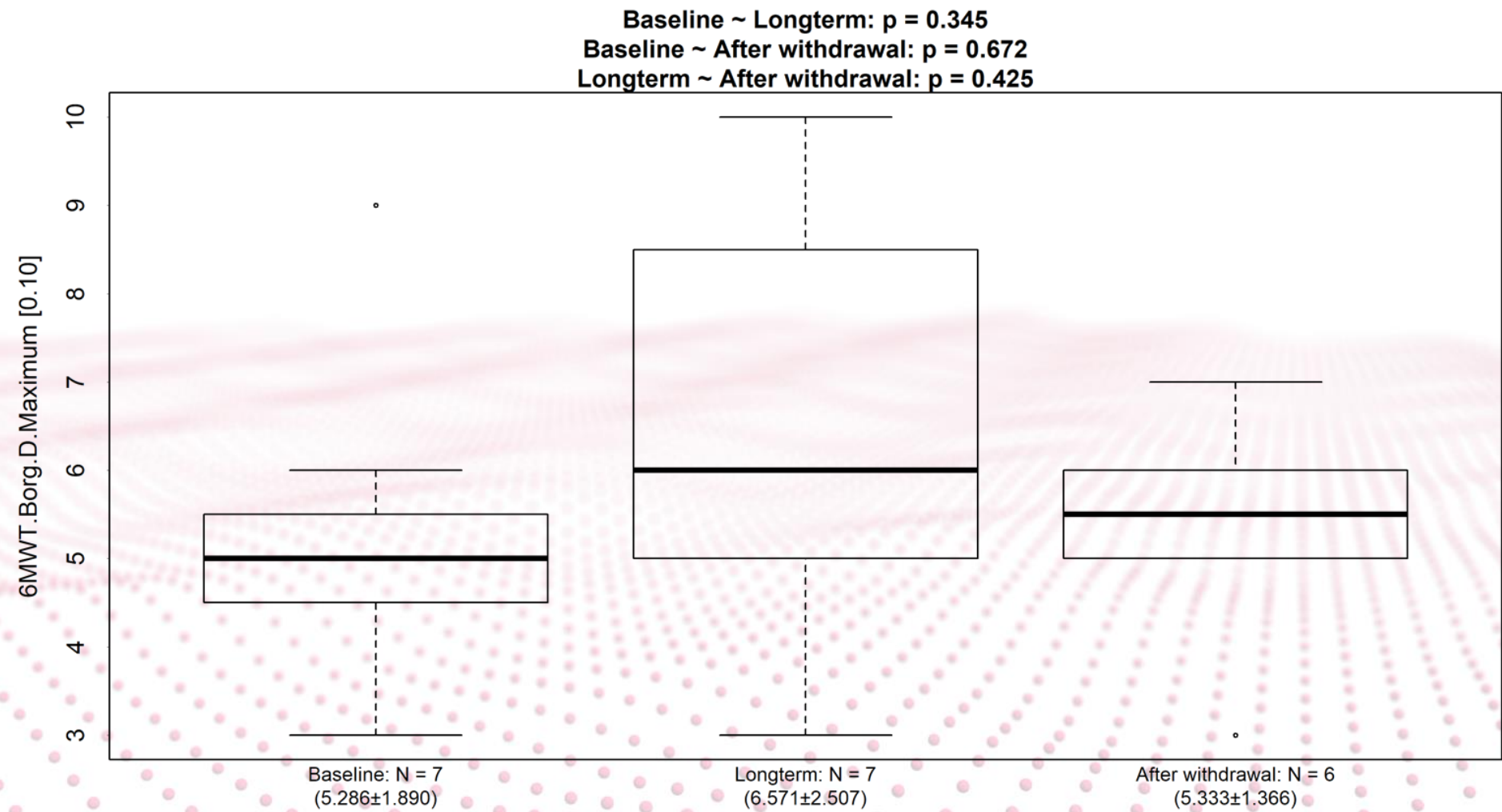
CLINICAL RESULTS – 6MWT



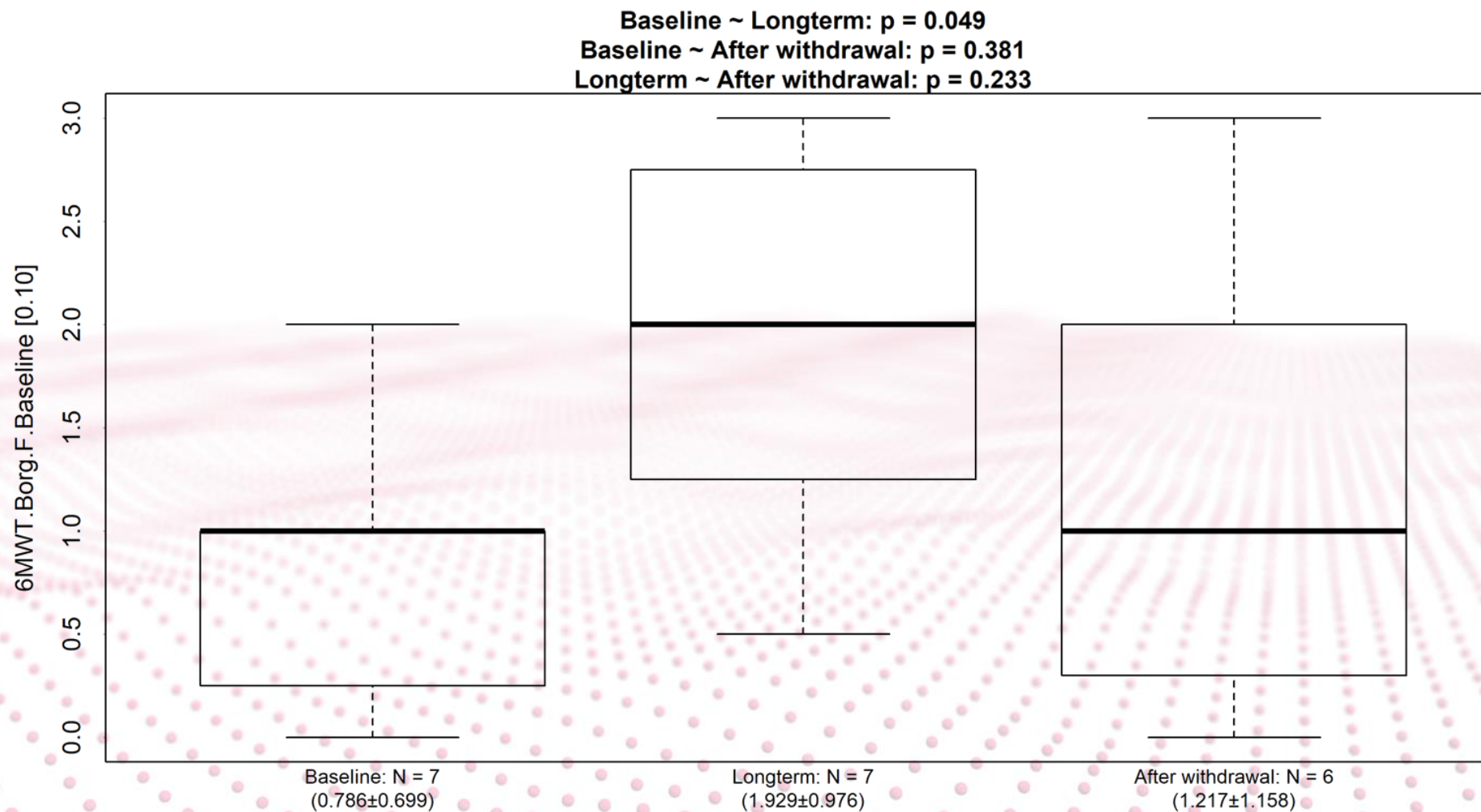
CLINICAL RESULTS – 6MWT



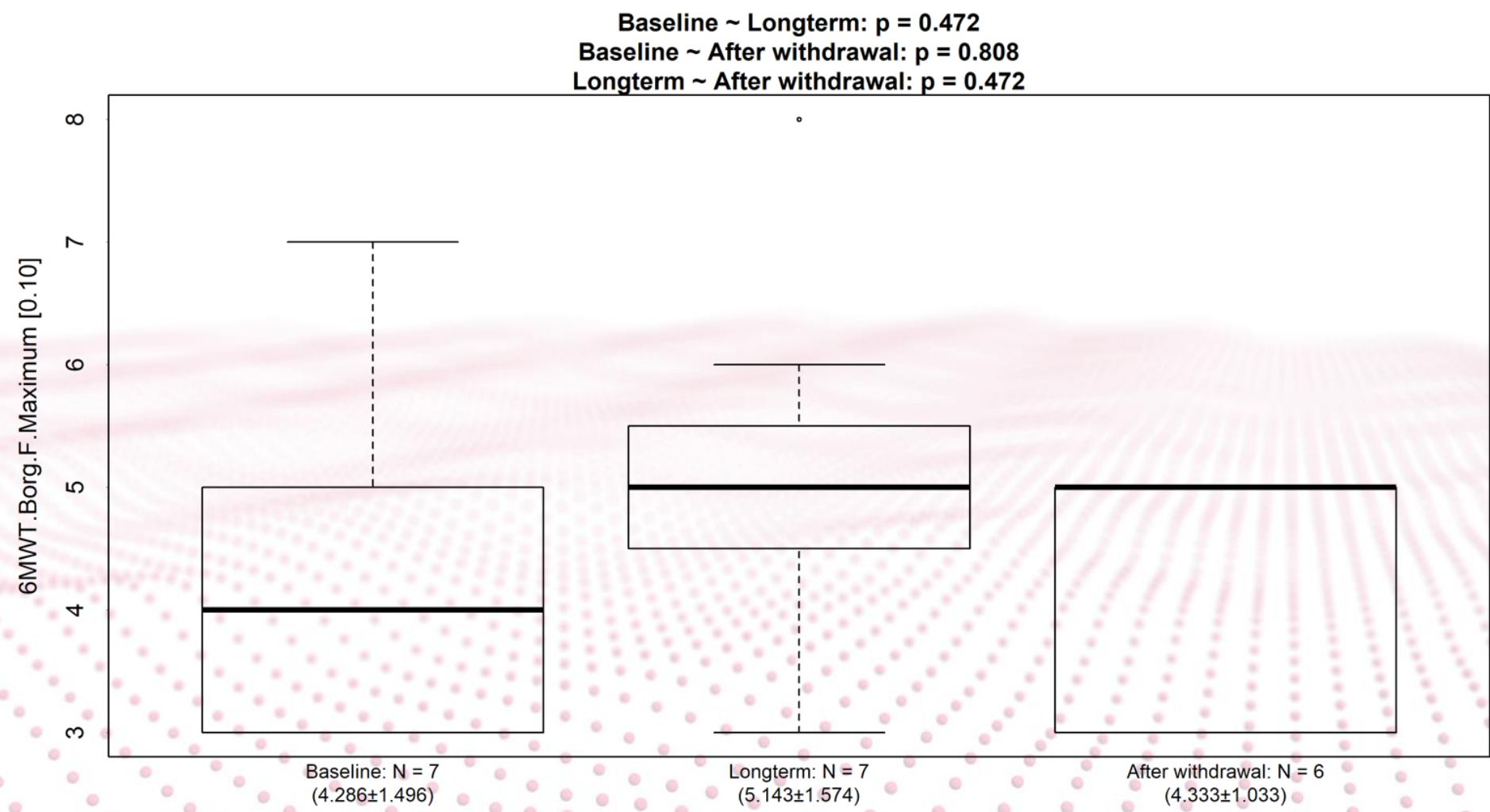
CLINICAL RESULTS – 6MWT



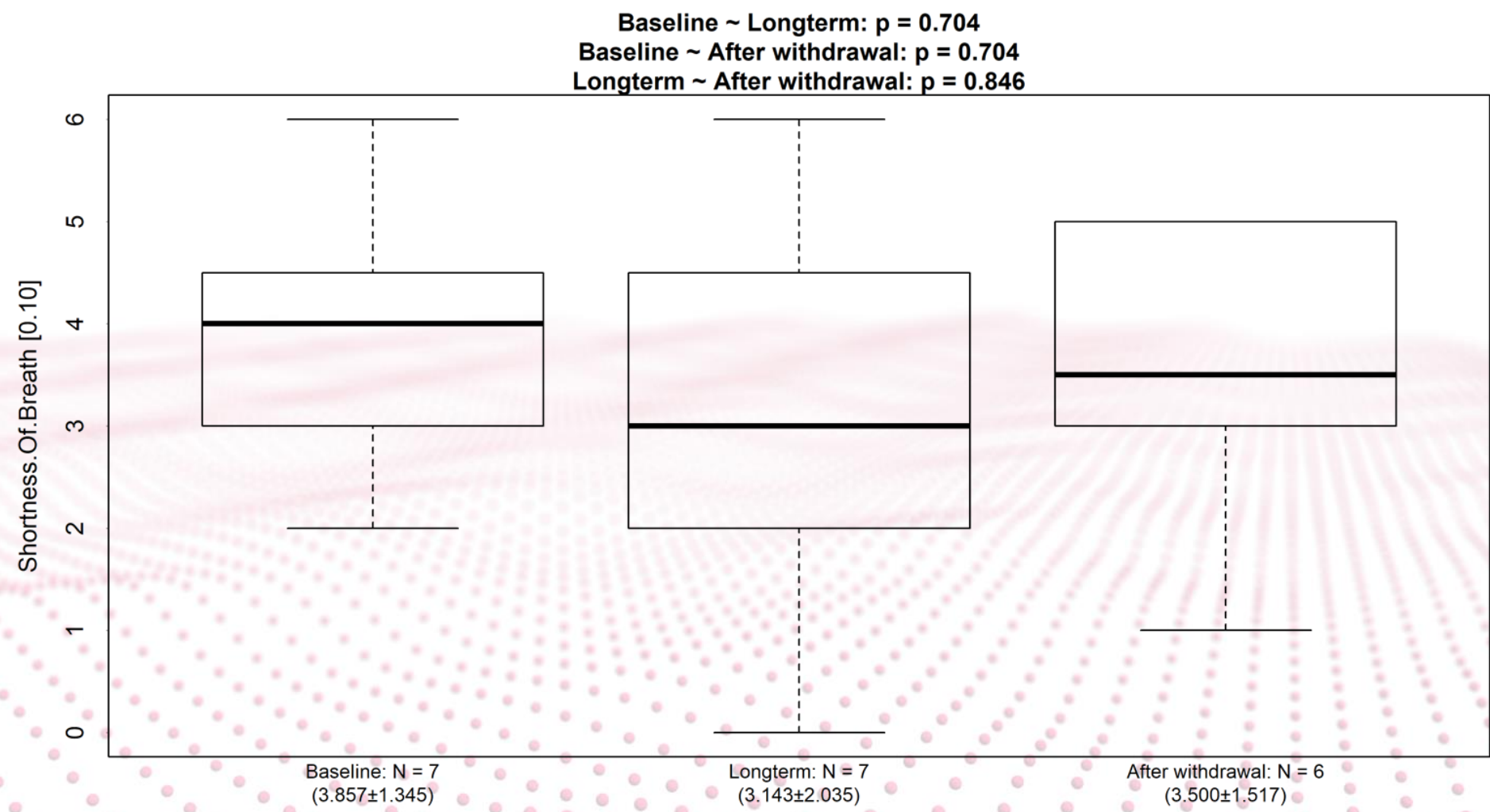
CLINICAL RESULTS – 6MWT



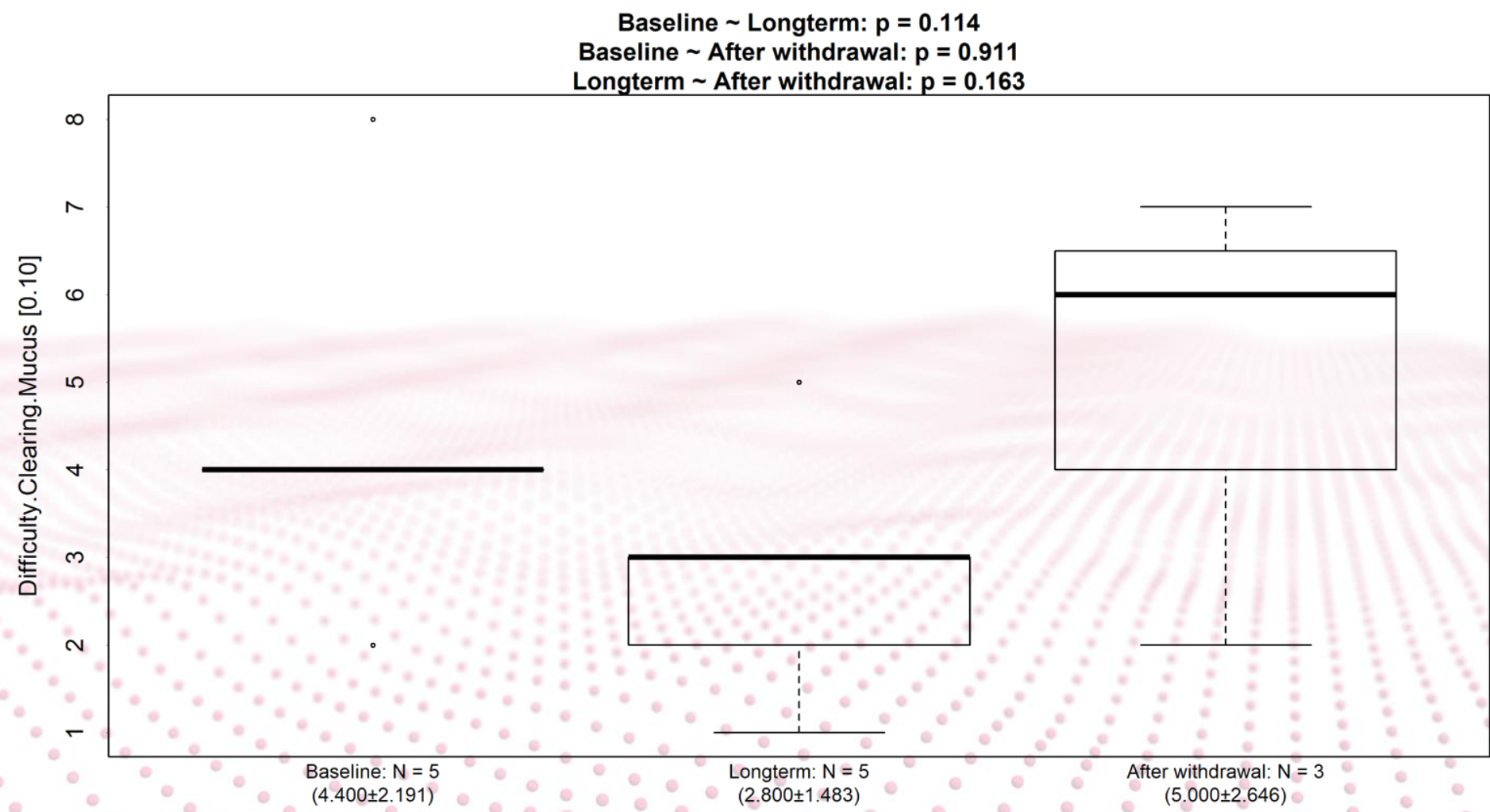
CLINICAL RESULTS – 6MWT



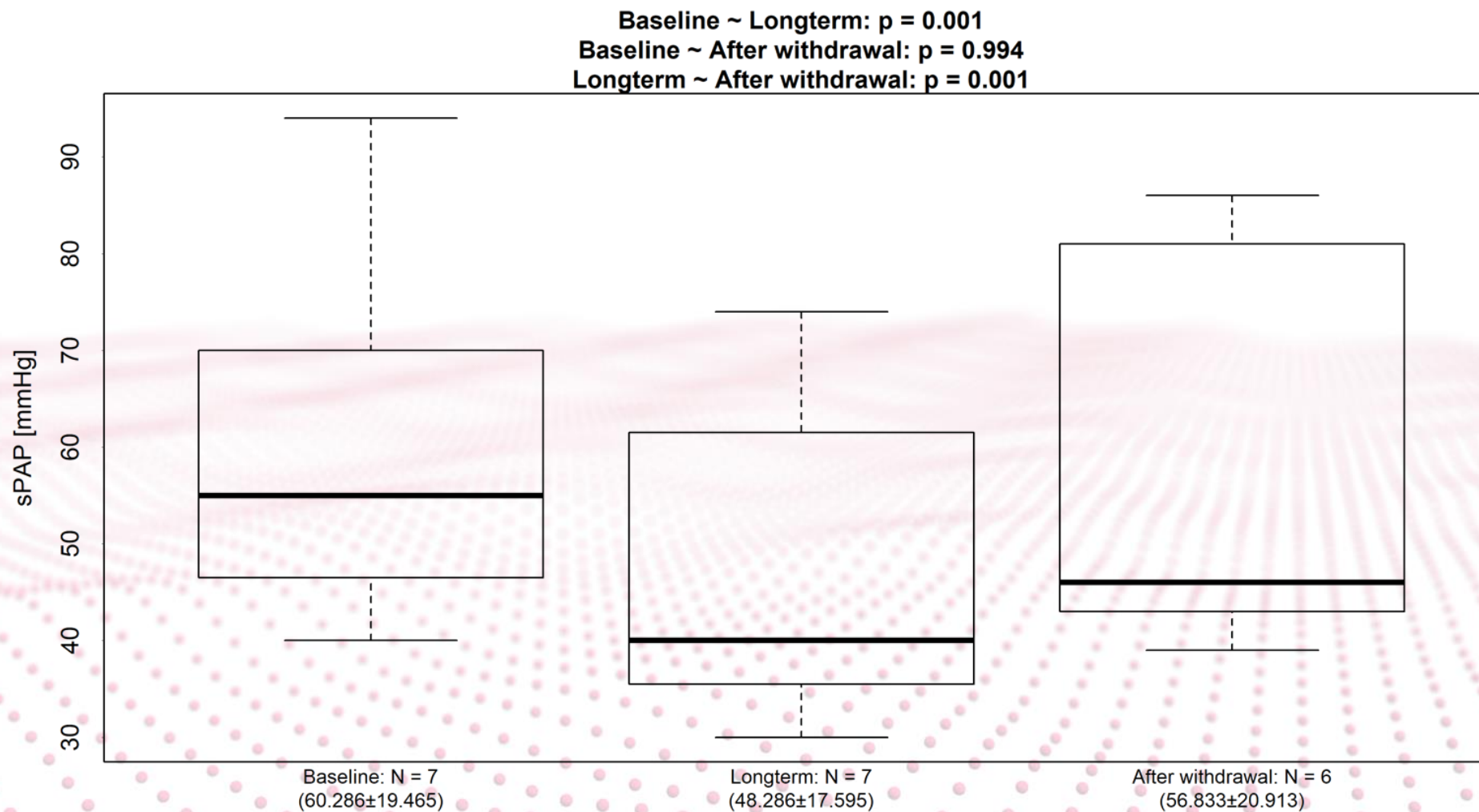
CLINICAL RESULTS – PRO



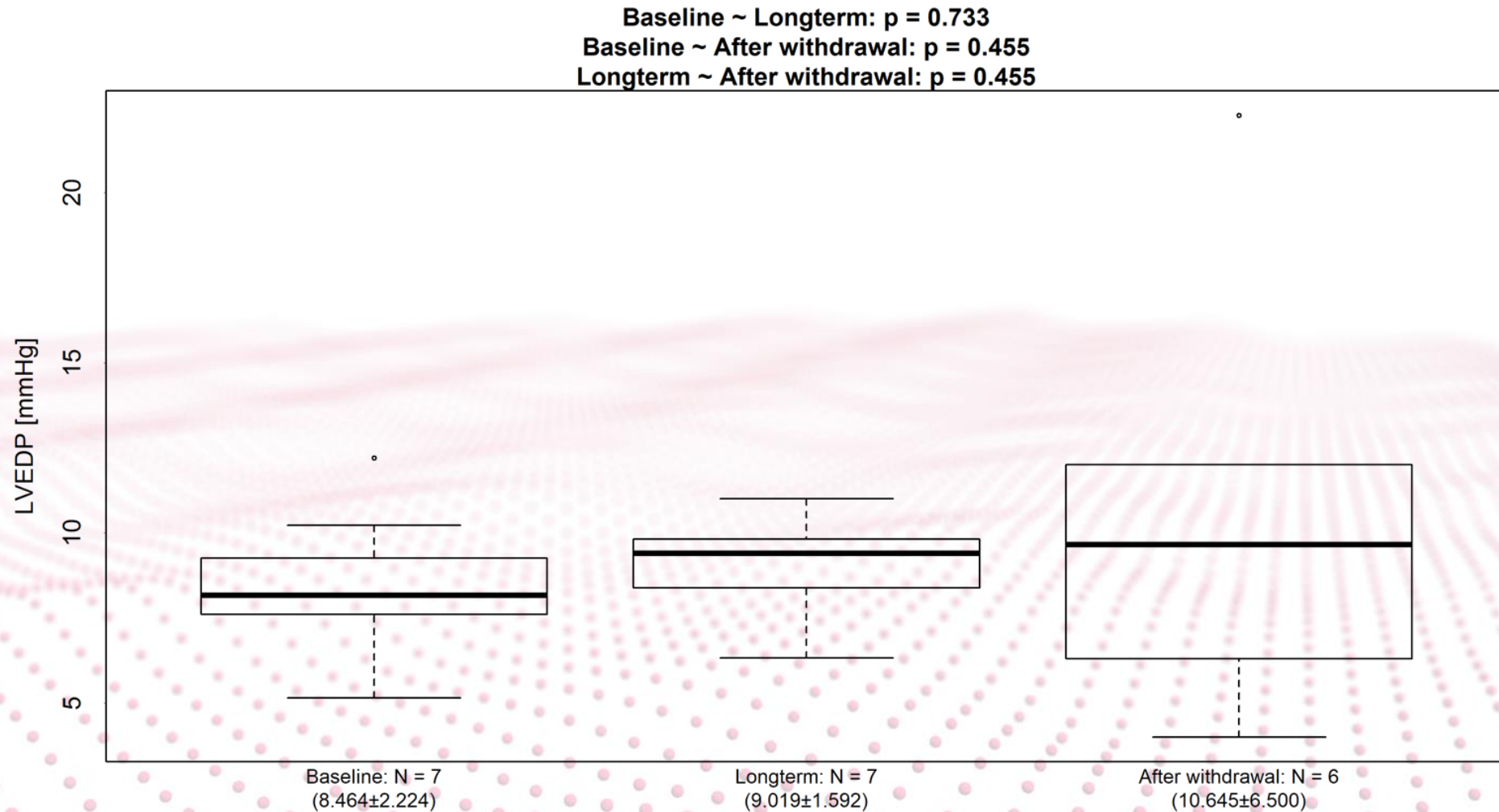
CLINICAL RESULTS – PRO



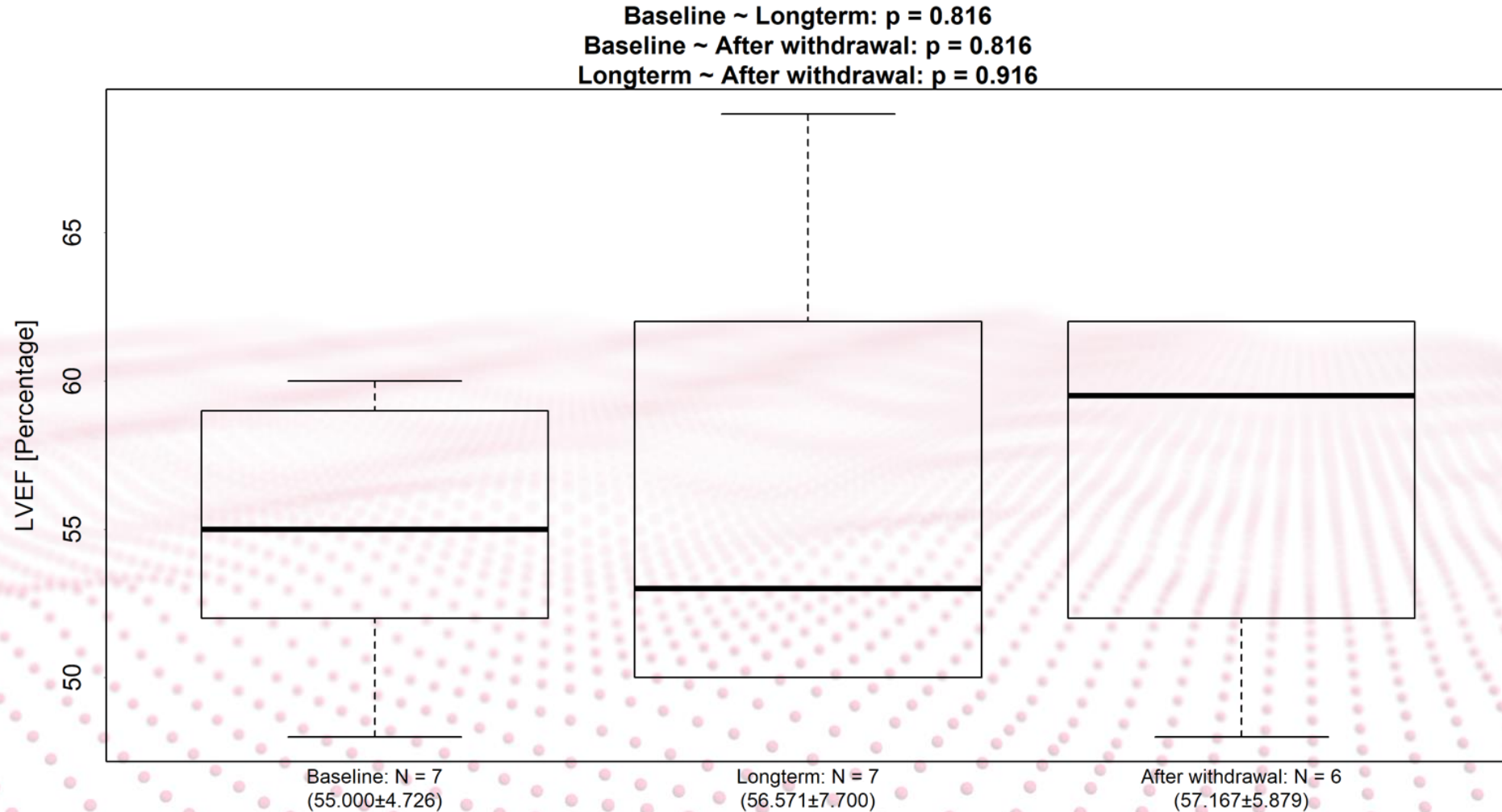
CLINICAL RESULTS – 2D Echocardiogram



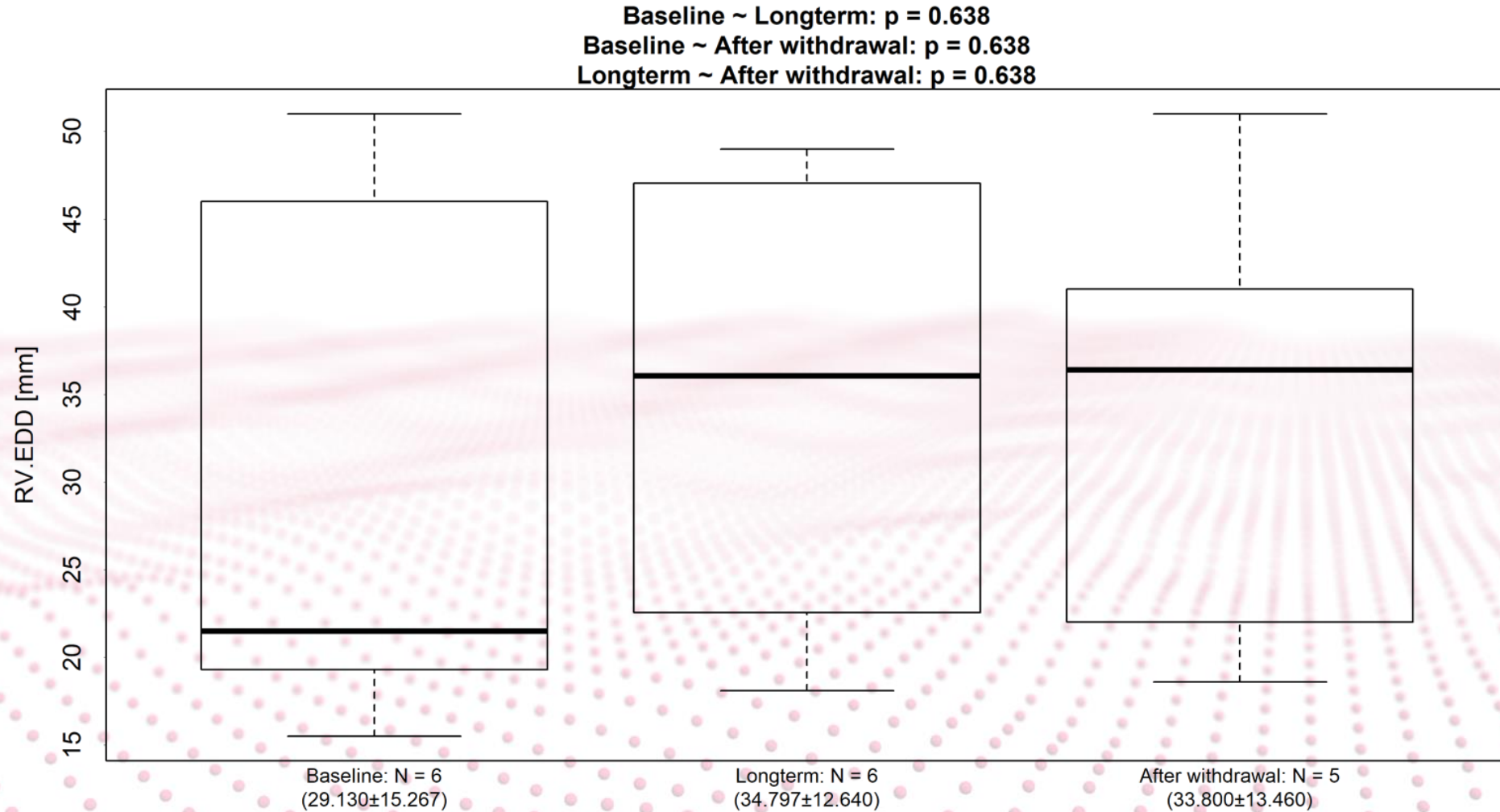
CLINICAL RESULTS – 2D Echocardiogram



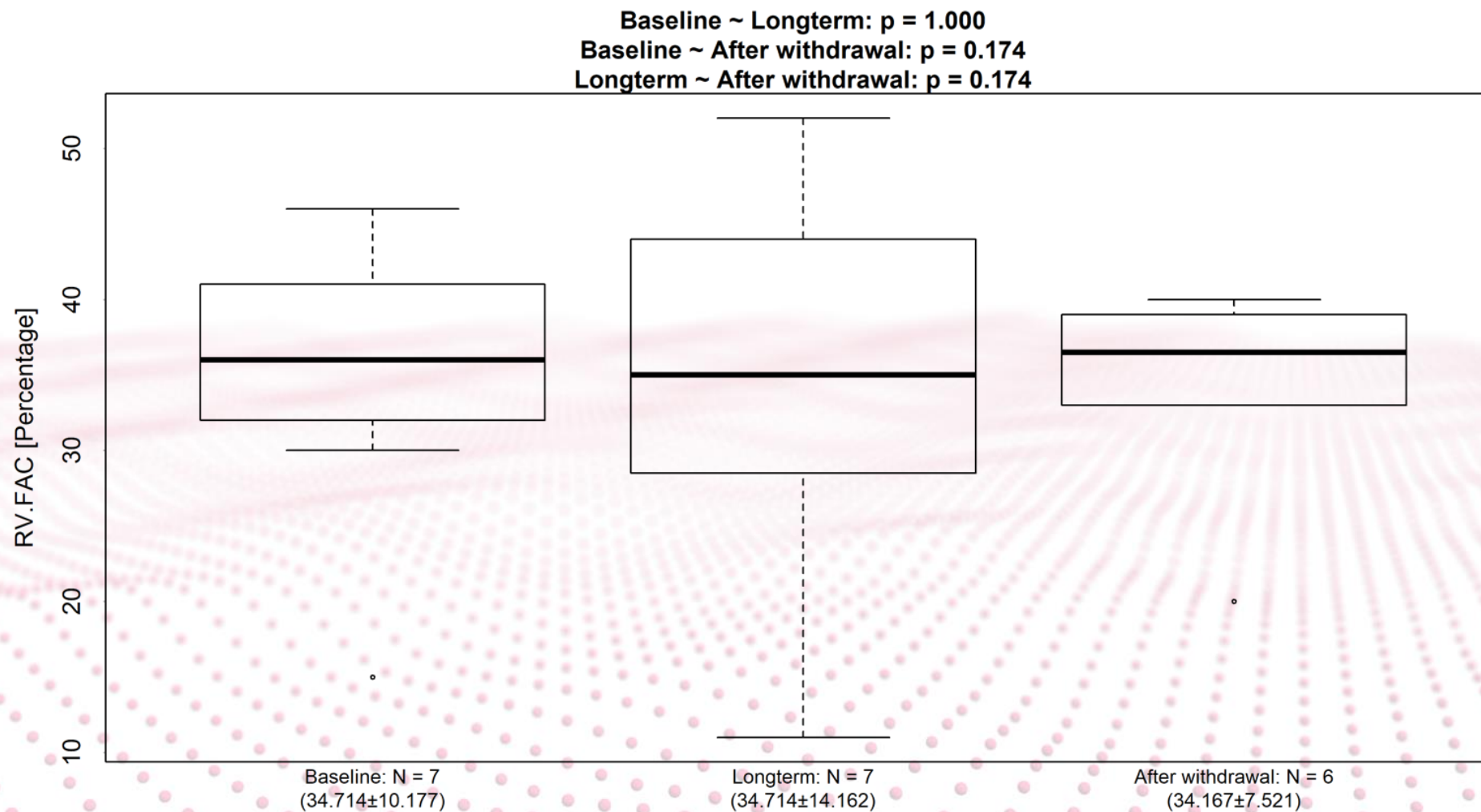
CLINICAL RESULTS – 2D Echocardiogram



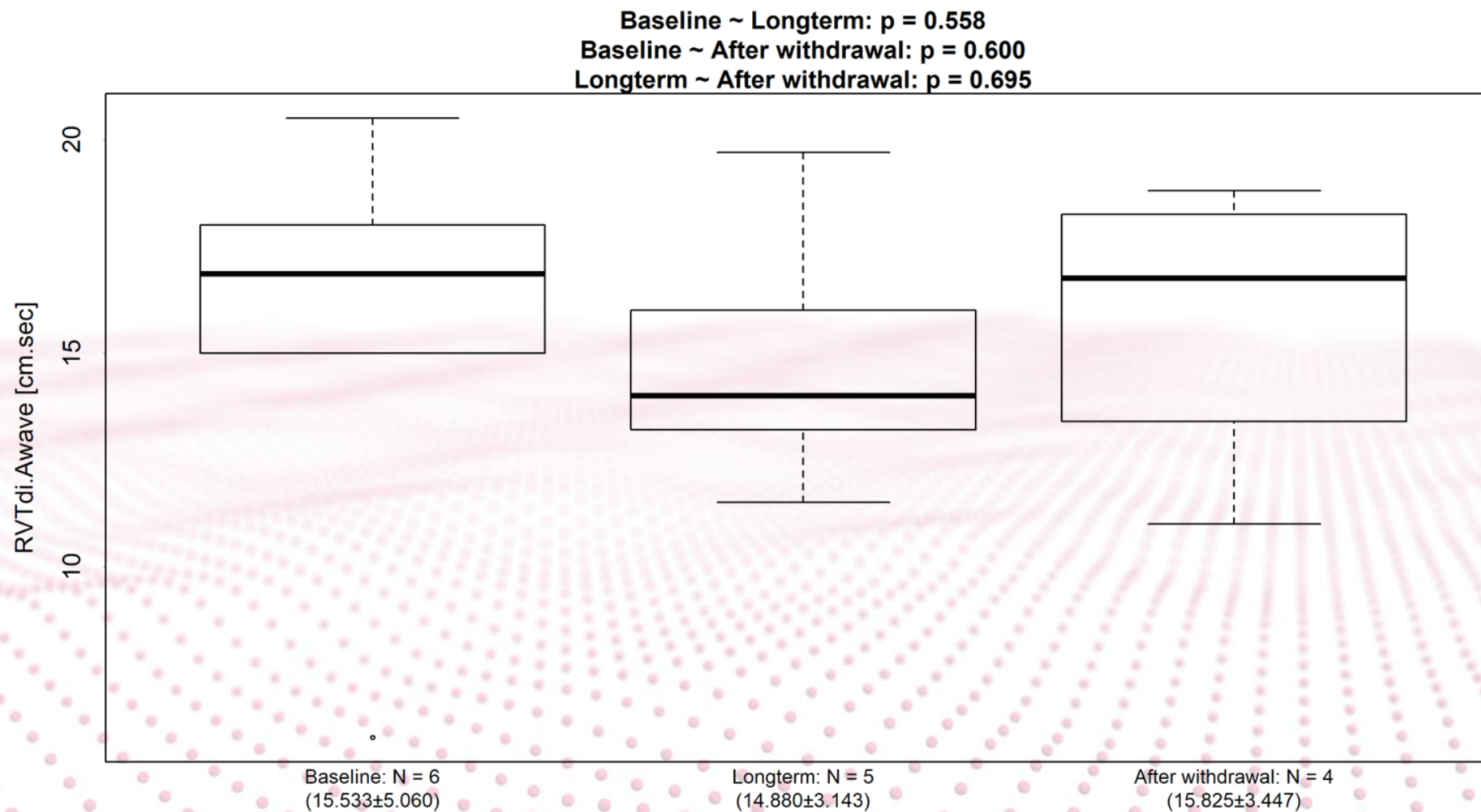
CLINICAL RESULTS – 2D Echocardiogram



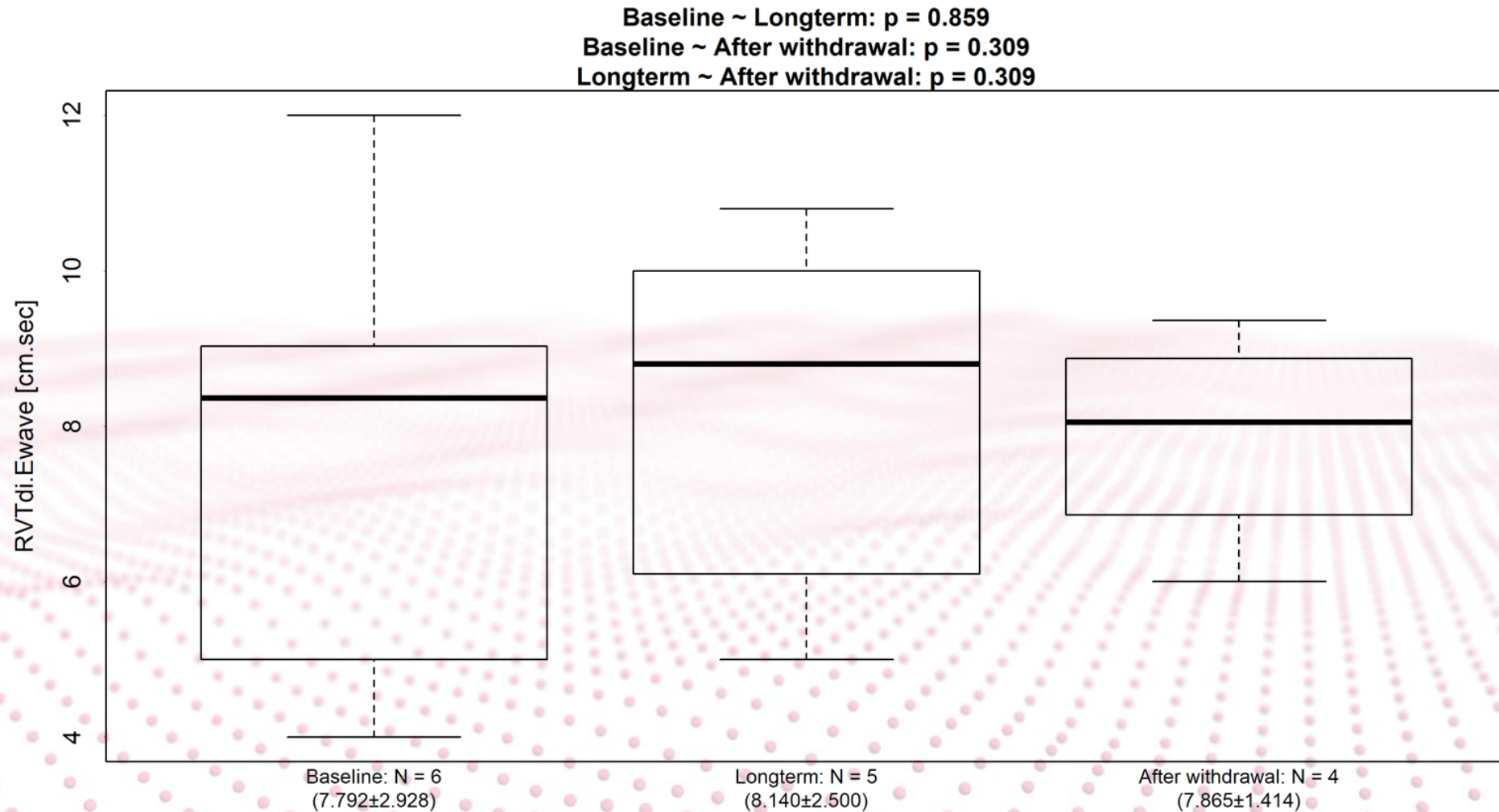
CLINICAL RESULTS – 2D Echocardiogram



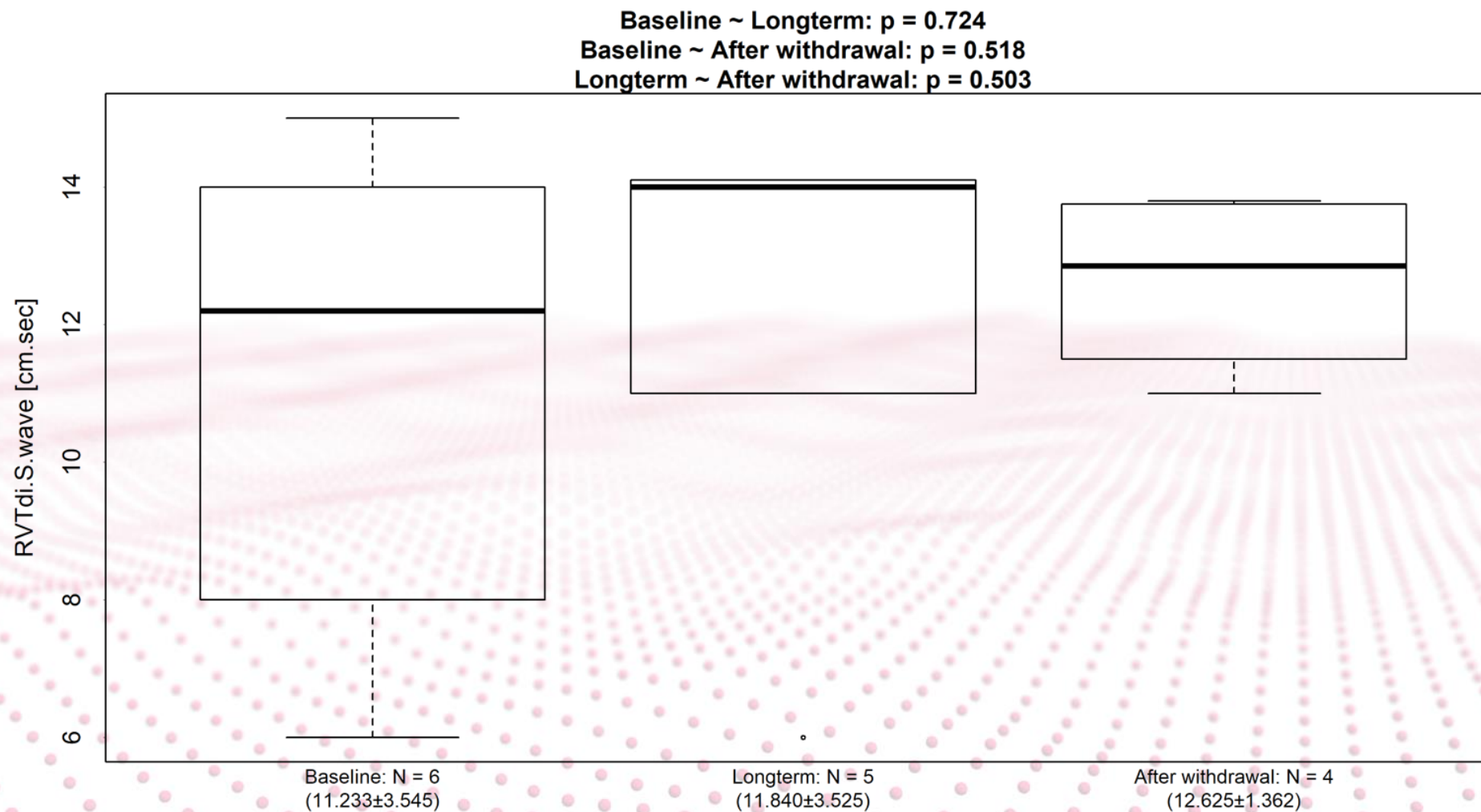
CLINICAL RESULTS – 2D Echocardiogram



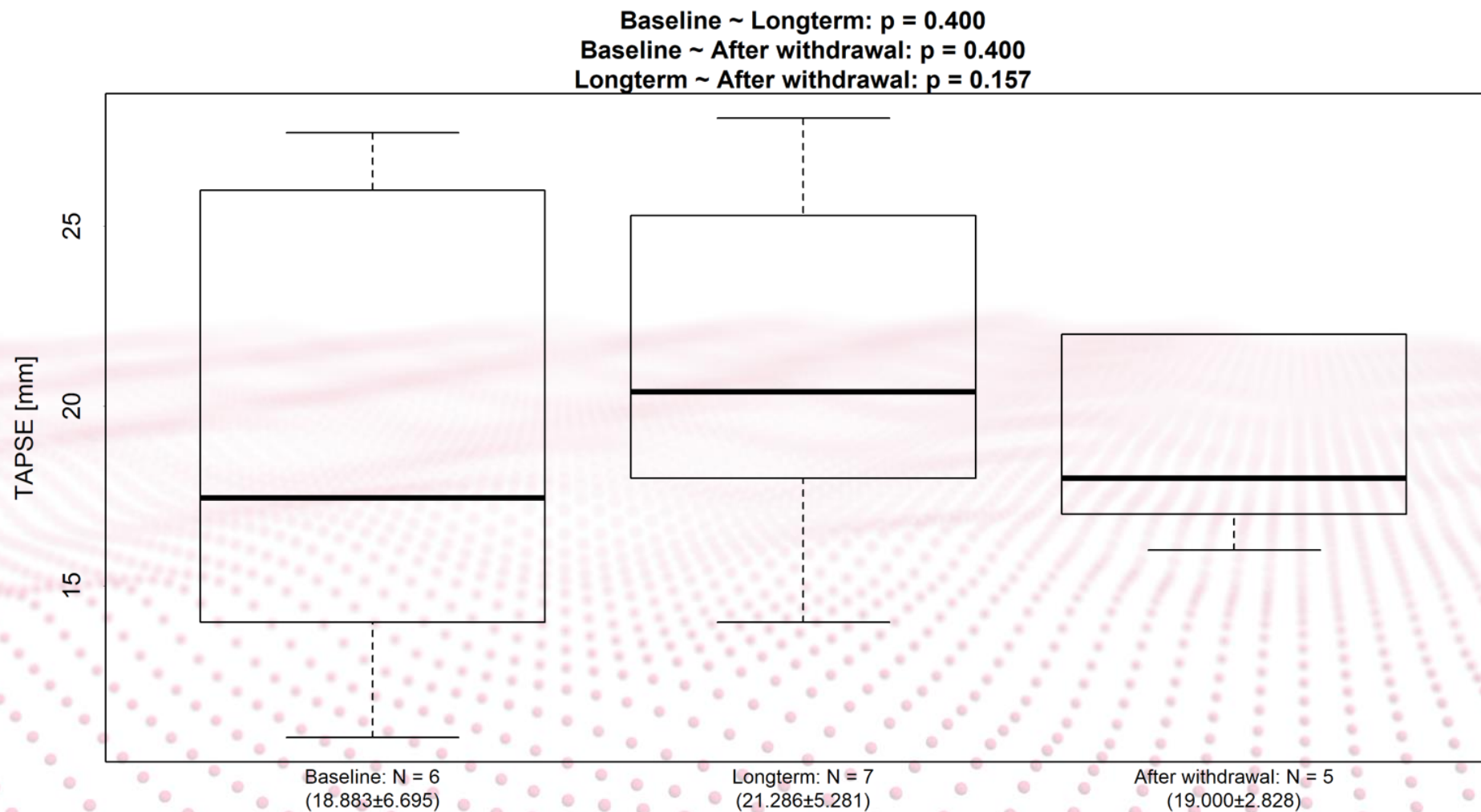
CLINICAL RESULTS – 2D Echocardiogram



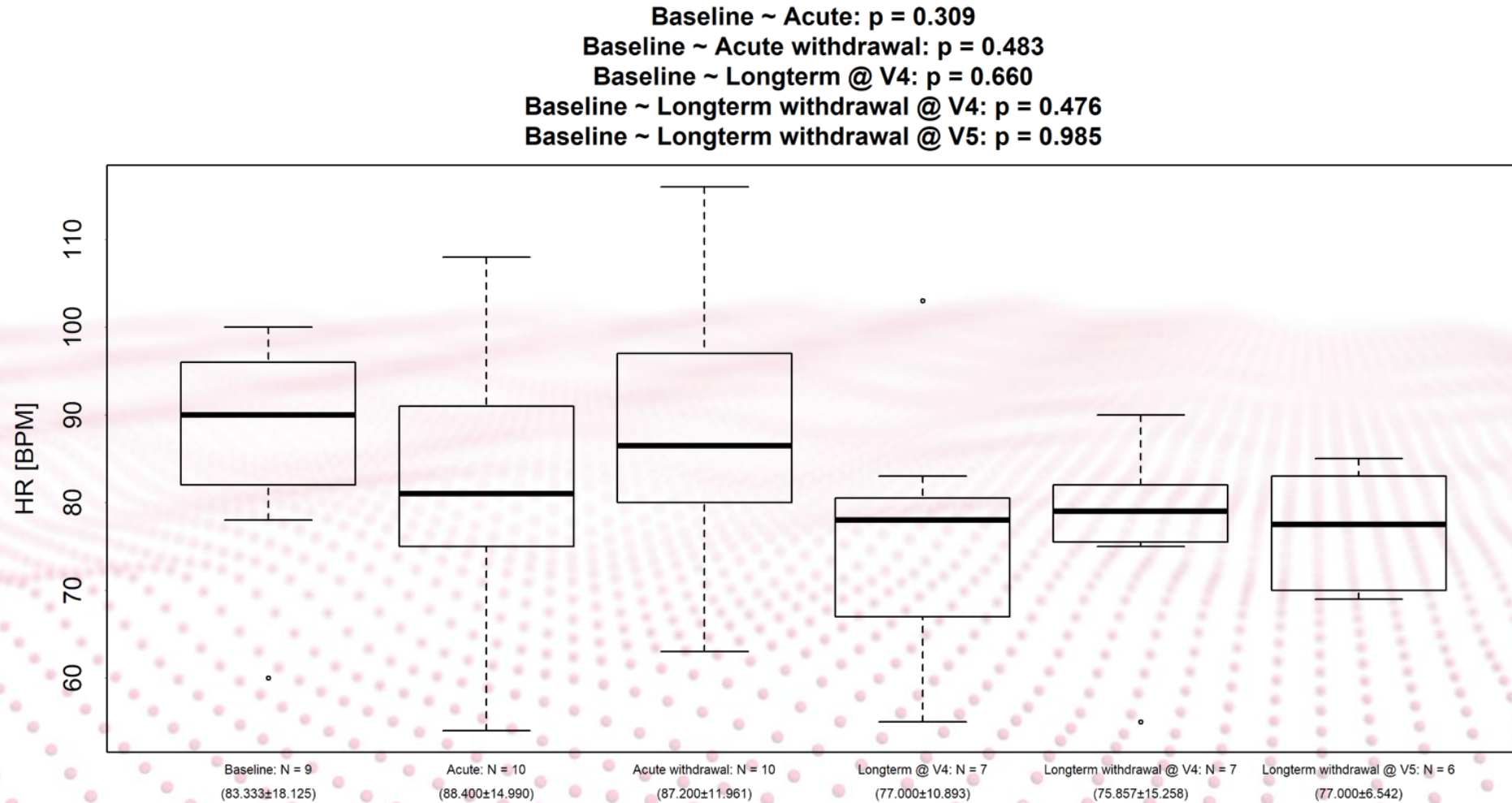
CLINICAL RESULTS – 2D Echocardiogram



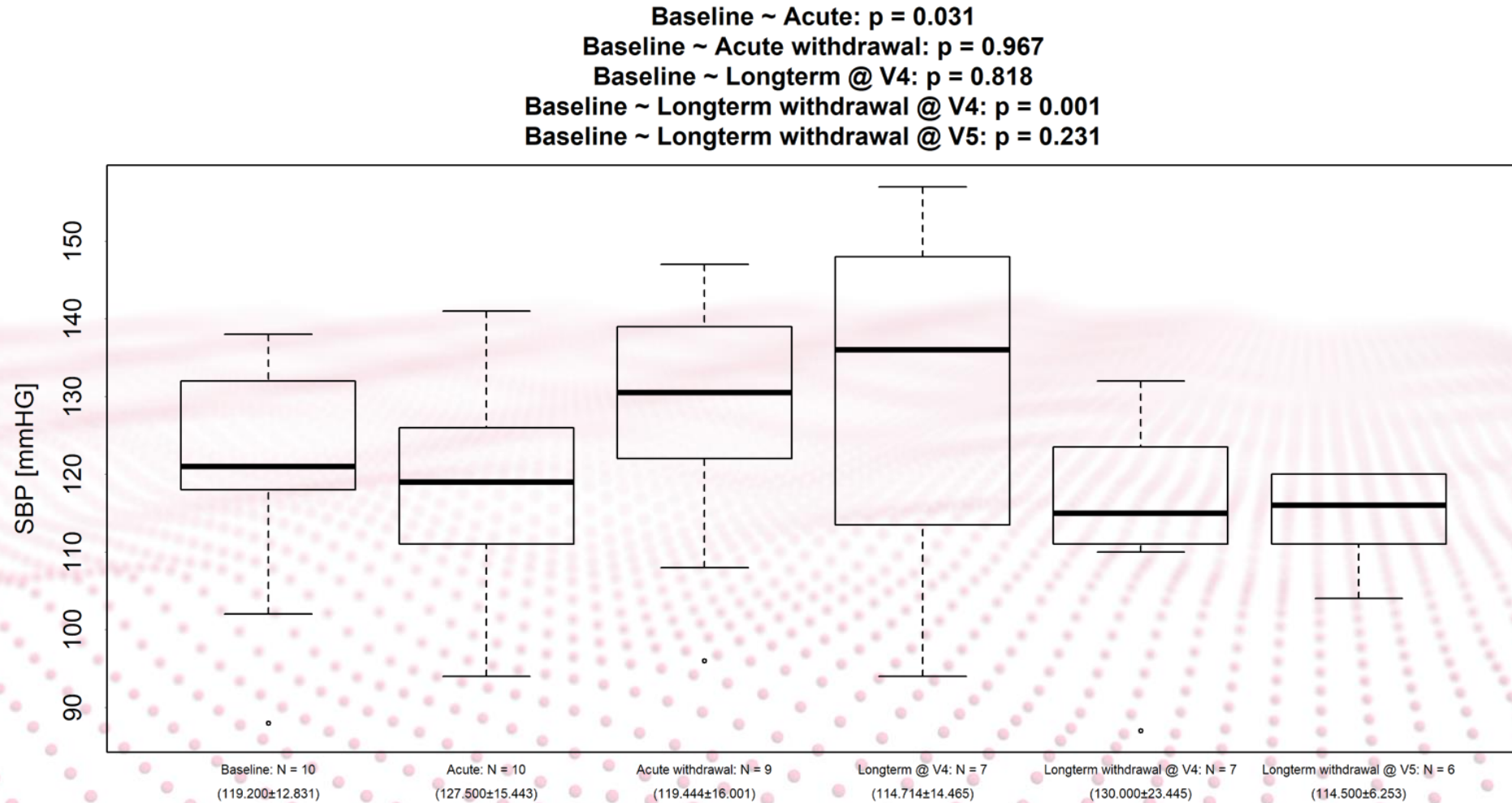
CLINICAL RESULTS – 2D Echocardiogram



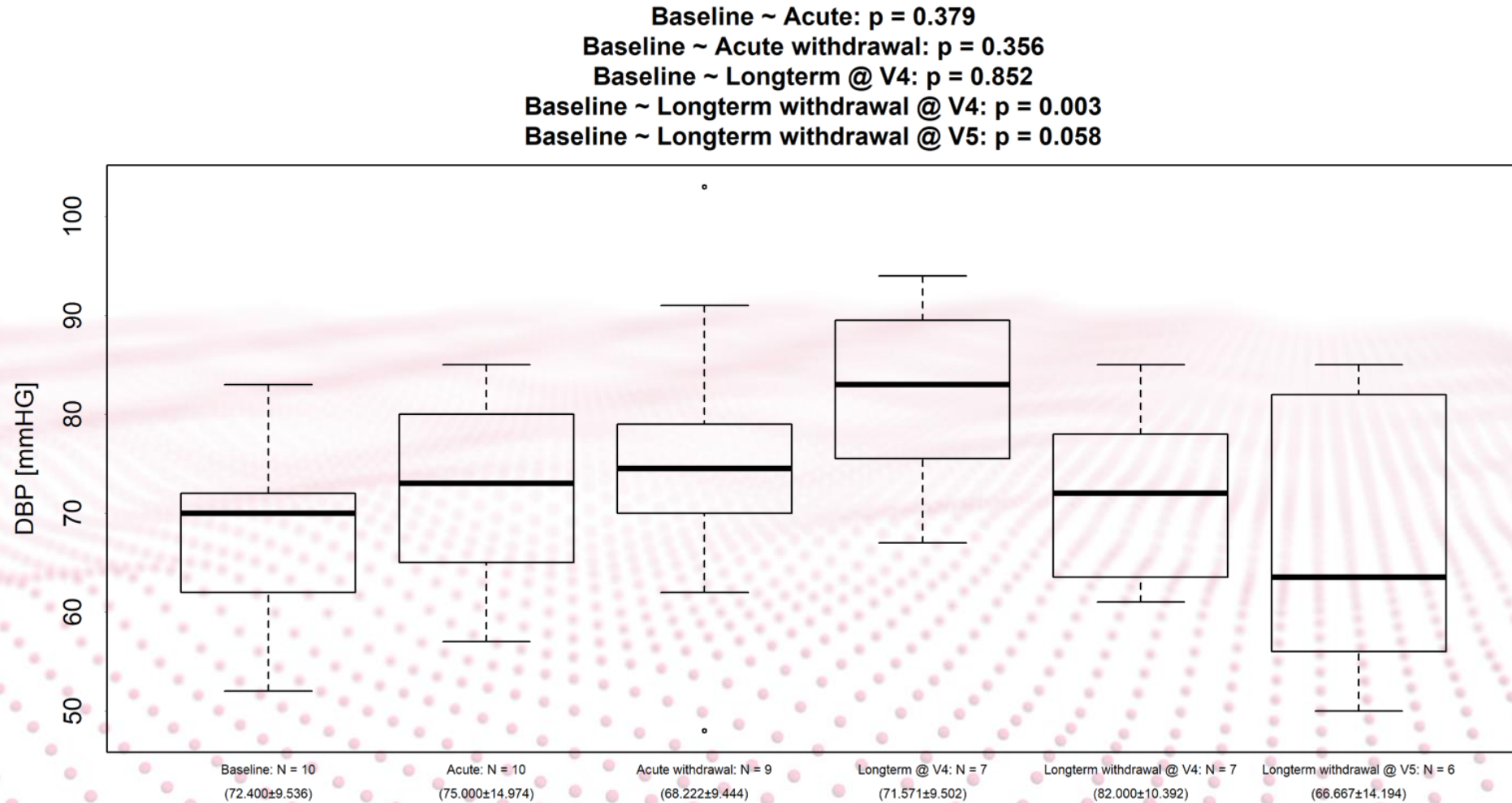
CLINICAL RESULTS – Vital signs



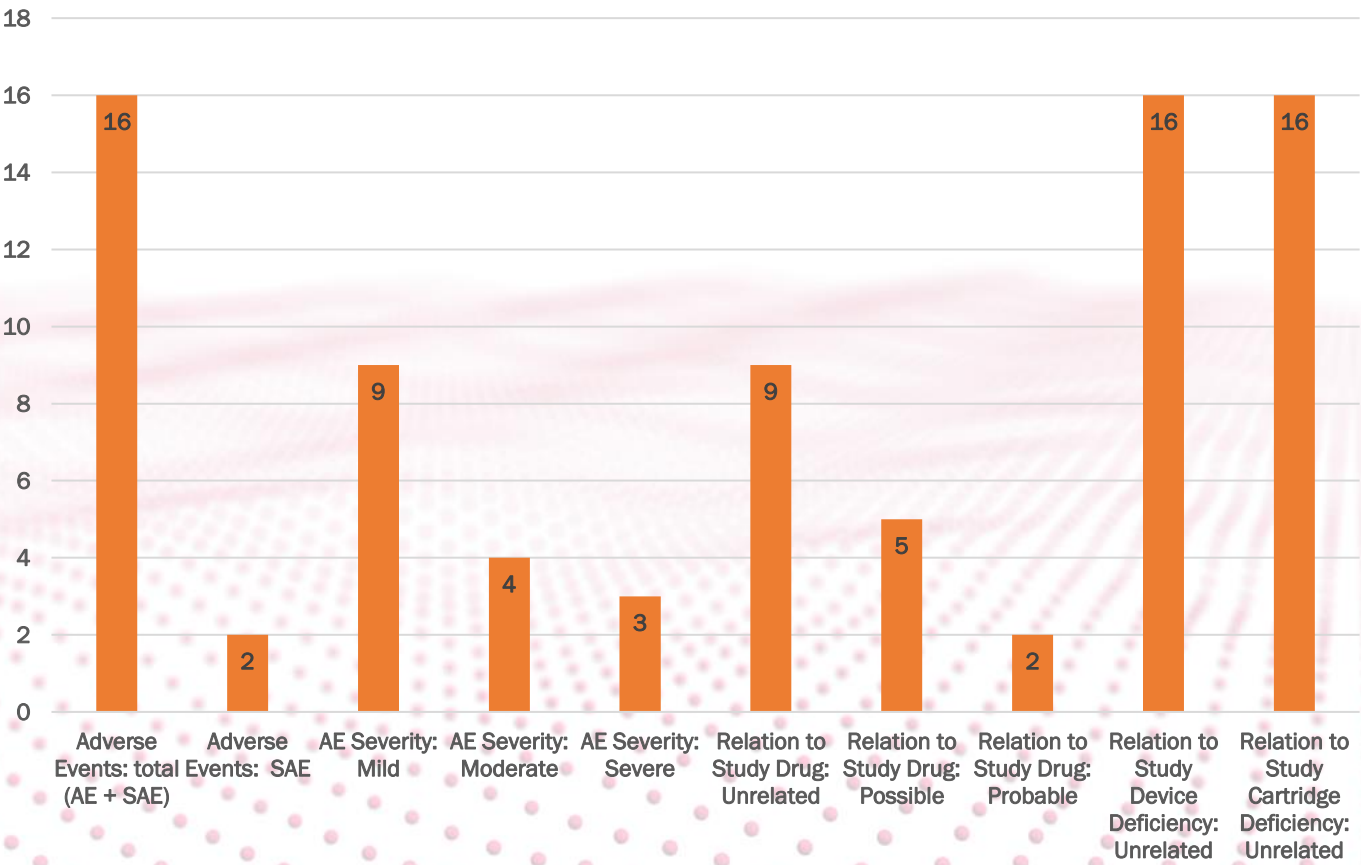
CLINICAL RESULTS – Vital signs



CLINICAL RESULTS – Vital signs



ADVERSE EVENT LIST



SAFETY

Subject	Form name	Adverse Event Name	Serious	Severity	Relation to Study Drug	Relation to Study Device Deficiency	Relation to Study Cartridge Deficiency	Action Taken with Study Drug	Outcome of Event
SUBJECT14	Adverse Event	Bad taste at the back of the throat	No	Mild	Unrelated	Unrelated	Unrelated	No Action Taken	Resolved
SUBJECT12	Adverse Event	Rebound PH with desaturation	No	Severe	Probable	Unrelated	Unrelated	Other, on remark page_Rebound PH: restart iNO	Resolved
SUBJECT9	Adverse Event	infectious COPD exacerbation hospitalisation	Yes	Severe	Unrelated	Unrelated	Unrelated	No Action Taken	Resolved
SUBJECT9	Adverse Event	infectious COPD exacerbation	No	Moderate	Unrelated	Unrelated	Unrelated	No Action Taken	Resolved
SUBJECT5	Adverse Event	unwell feeling	No	Moderate	Possible	Unrelated	Unrelated	No Action Taken	Resolved
SUBJECT5	Adverse Event	Lung nodules	No	Mild	Unrelated	Unrelated	Unrelated	No Action Taken	Ongoing
SUBJECT10	Adverse Event	left eye infection	No	Mild	Unrelated	Unrelated	Unrelated	No Action Taken	Resolved
SUBJECT11	Adverse Event	COPD exacerbation	No	Moderate	Unrelated	Unrelated	Unrelated	No Action Taken	Ongoing
SUBJECT11	Adverse Event	nausea	No	Moderate	Probable	Unrelated	Unrelated	Study Drug Permanently Discontinued	Resolved
SUBJECT11	Adverse Event	diarrhea	No	Mild	Unrelated	Unrelated	Unrelated	No Action Taken	Resolved
SUBJECT11	Adverse Event	nausea	No	Mild	Possible	Unrelated	Unrelated	No Action Taken	Resolved
SUBJECT6	Adverse Event	nose pain from cannula	No	Mild	Unrelated	Unrelated	Unrelated	No Action Taken	Resolved
SUBJECT5	Adverse Event	dyspnea	No	Mild	Possible	Unrelated	Unrelated	No Action Taken	Ongoing
SUBJECT5	Adverse Event	hypercapnia	No	Mild	Possible	Unrelated	Unrelated	No Action Taken	Resolved with Sequelae
SUBJECT5	Adverse Event	headache	No	Mild	Possible	Unrelated	Unrelated	No Action Taken	Unknown
SUBJECT2	Adverse Event	Large suspect mass in left lower lobe	Yes	Severe	Unrelated	Unrelated	Unrelated	No Action Taken	Ongoing