







Preoperative imaging in primary hyperparathyroidism: Are ^{11}C -Choline PET/CT and $^{99\text{m}}\text{Tc}$ -MIBI/ ^{123}I odide subtraction SPECT/CT interchangeable or do they supplement each other?

Julie W. Christensen¹  | Afefah Ismail^{1,2} | Susanne B. Søndergaard¹  |
 Finn N. Bennedbæk³  | Birte Nygaard³  | Lars T. Jensen¹  |
 Waldemar Trolle⁴ | Christoffer Holst-Hahn⁵ | Bo Zerahn¹ | Bent Kristensen¹ |
 Martin Krakauer^{1,2} 

¹Department of Nuclear Medicine, Herlev and Gentofte Hospital, Herlev, Denmark

²Department of Clinical Physiology and Nuclear Medicine, Bispebjerg and Frederiksberg Hospital, Copenhagen, Denmark

³Division of Endocrinology, Department of Medicine, Herlev and Gentofte Hospital, Herlev, Denmark

⁴Department of Otorhinolaryngology and Neck Surgery, North Zealand Hospital, Hillerød, Denmark

⁵Department of Otorhinolaryngology and Neck Surgery, Rigshospitalet, Copenhagen, Denmark

Correspondence

Julie W. Christensen, Department of Nuclear Medicine, Herlev & Gentofte Hospital, Borgmester Ib Juuls Vej 71, 2730 Herlev, Denmark.
 Email: juliewulfc@gmail.com

Funding information

Scientific Committee of Herlev University Hospital

Abstract

Objective: Preoperative location of hyperfunctioning parathyroid glands (HPGs) is vital when planning minimally invasive surgery in patients with primary hyperparathyroidism (PHPT). Dual-isotope subtraction scintigraphy with $^{99\text{m}}\text{Tc}$ -MIBI/ ^{123}I odide using SPECT/CT and planar pinhole imaging (Di-SPECT) has shown high sensitivity, but is challenged by high radiation dose, time consumption and cost. ^{11}C -Choline PET/CT (faster with a lower radiation dose) is non-inferior to Di-SPECT. We aim to clarify to what extent the two are interchangeable and how often there are discrepancies.

Design: This is a prospective, GCP-controlled cohort study.

Patients and Measurements: One hundred patients diagnosed with PHPT were included and underwent both imaging modalities before parathyroidectomy. Clinical implications of differences between imaging findings and negative imaging results were assessed. Surgical findings confirmed by biochemistry and pathology served as reference standard.

Results: Among the 90 patients cured by parathyroidectomy, sensitivity was 82% (95% confidence interval [CI]: 74%–88%) and 87% (95% CI: 79%–92%) for Choline PET and Di-SPECT, respectively, $p = .88$. In seven cases at least one imaging modality found no HPG. Of these, neither modality found any true HPGs and only two were cured by surgery. When a positive finding in one modality was incorrect, the alternative modality was correct in approximately half of the cases.

Conclusion: Choline PET and Di-SPECT performed equally well and are both appropriate as first-line imaging modalities for preoperative imaging of PHPT. When the first-line modality fails to locate an HPG, additional preoperative imaging with the alternate modality offers no benefit. However, if parathyroidectomy is

unsuccessful, additional imaging with the alternate modality has merit before repeat surgery.

KEYWORDS

^{11}C -Choline PET/CT, $^{99\text{m}}\text{Tc}$ -MIBI/ ^{123}I odide subtraction SPECT/CT, hyperparathyroidism, method comparison, parathyroidectomy, preoperative imaging, prospective cohort

1 | INTRODUCTION

Primary hyperparathyroidism (PHPT) is caused by one or more hyperfunctioning parathyroid glands (HPGs). An increase in plasma parathyroid hormone (PTH) results in bone loss and increases the risk of kidney stones. Symptoms may be mild and nonspecific but can involve numerous organ systems, including gastrointestinal, metabolic, musculoskeletal, and cerebral systems. PHPT is fairly common, with over 100 new cases annually per million Danish citizens, and primarily affects women aged 40–70 years.^{1–3}

Diagnosis is often based on an incidental finding of hypercalcaemia and standard curative treatment is parathyroidectomy (PTx), with the most common indications in Denmark being: P-Ca⁺⁺ repeatedly >1.45 mmol/L or mild hypercalcaemia (P-Ca⁺⁺ 1.32–1.45 mmol/L) combined with age <50 years, reduced creatinine clearance, BMD T-score < -2.5 in lumbar spine, hip or distal forearm, low-energy fracture, kidney stones or nephrocalcinosis, and peptic ulcer.^{1,3,4}

Due to the small size of HPG(s), preoperative visualisation and localisation are imperative for the surgeon to plan minimally invasive surgery. Several imaging methods are available for this purpose. One widely used method is dual-isotope subtraction parathyroid scintigraphy with $^{99\text{m}}\text{Tc}$ -MIBI and ^{123}I odide including SPECT/CT and planar pinhole imaging (Di-SPECT), which has a high diagnostic accuracy (sensitivity 82%–93%^{5–7}) and was proven superior to both single-isotope MIBI planar and SPECT/CT imaging and to dual-isotope subtraction scintigraphy with single isotope SPECT/CT (sensitivities 17%–89%).^{5–10} Due to the high cost, time consumption (≤ 4.5 h) and radiation dose (≈ 13 mSv) alternative modalities such as positron emission tomography/computed tomography (PET/CT) using carbon-11-labelled choline (^{11}C -Choline) as the tracer (Choline PET) have been evaluated and found promising with sensitivity as high as 87%–97%.^{11–14}

Other widely used methods include 4D-CT and ultrasound, both of which have previously been found to have varying sensitivity, 55%–85% and 29%–81%, respectively.^{5,7,15–17} Additionally, the accuracy of any method will be affected by local availability and expertise.

This prospective cohort study compares the performance of Choline PET and our standard method (Di-SPECT) using surgical findings, confirmed by pathology and intra- and postoperative biochemistry, as the reference standard. We have previously found Choline PET to be non-inferior to Di-SPECT. Here, we investigate whether the two modalities find the same HPGs, or whether they differ and would therefore be supplementary to each other.

Choline PET is preferable with regard to acquisition time, radiation burden and cost but is only accessible in centres with access to a cyclotron. Therefore, the first-line modality will vary depending on availability. With this study we hope to clarify when one modality may be more effective than the other, and if the alternate method contributes additional information if the first one fails.

2 | MATERIALS AND METHODS

The study was conducted in accordance with the Helsinki 2 declaration and the International Council for Harmonisation Guideline for Good Clinical Practice (ICH_GCP), approved by the Research Ethics Committee of the Capital Region of Denmark (Journal-nr.: H-18012490, date of approval: 18 June 2018) and the Danish Medicines Agency (EudraCT no. 2018-000726-63, date of approval: 6 June 2018). The GCP-unit in Eastern Denmark has carried out regular monitoring of the trial in accordance with GCP (ID: 2018-1050; GCP: Good Clinical Practice).

2.1 | Patients

Patients were included consecutively from the Department of Medicine, Division of Endocrinology, Herlev and Gentofte Hospital, Denmark, from 19 August 2018 to 7 September 2020. All patients were diagnosed with PHPT. For details on inclusion and exclusion criteria, please refer to our previous publication.¹³

P-Ca⁺⁺, P-PTH and 25-OH-vitamin D were routinely measured before and after surgery. Any patient with low 25-OH-vitamin D immediately commenced vitamin D3 supplements, and normalisation of vitamin D status was documented in all patients before surgery.

Written consent has been obtained from each patient after full information of the purpose and nature of all procedures used.

2.2 | Image acquisition and analysis

The order of Choline PET and Di-SPECT scans varied depending on availability.

All images were analysed by one of two nuclear medicine specialists, each an expert in their respective imaging modality (Choline PET or Di-SPECT). Readers recorded the number of HPGs and their location relative to the thyroid gland as well as the readers' subjective

certainty of each individual assessment ('low', 'moderate' or 'high'). Readers were blinded to each other's results.

Planar pinhole and SPECT/CT images were acquired on a Philips Skylight gamma-camera (Philips Healthcare) and a Siemens Symbia Intevo SPECT/CT scanner (Siemens Healthineers), respectively, in the Department of Nuclear Medicine, Herlev and Gentofte Hospital, Denmark. CT was performed as a non-enhanced diagnostic scan while pinhole and SPECT parameters were performed as previously published⁵ except that the SPECT acquisition was performed as a dual-isotope scan.

¹¹C-Choline was synthesized in the Cyclotron and Radiochemistry Unit at the same department using the Scansys synthesis module (Scansys Laborieteknik). Acquisition started 10 min (± 5 min) after injection of 400 MBq on a Siemens Biograph mCT 64 slice (Siemens Healthineers). CT scans were performed in diagnostic quality without contrast.

Di-SPECT images were analysed using Oasis software (Segami, Columbia), MIM (MIM Software Inc.) and Choline PET images were analysed using Syngo.Via (Siemens Healthineers). Please refer to our previous publication for further acquisition and analysis details.¹³

See Figure 1 for typical images of a patient with parathyroid adenoma, and Figure 2 for images of a patient with parathyroid hyperplasia.

2.3 | Surgery and follow-up

Surgery was performed by one of eight head and neck surgeons with extensive thyroid/parathyroid experience. Results from both imaging modalities were available preoperatively. An intraoperative P-PTH decrease of $\geq 50\%$ or normalisation indicated successful surgery. In case of minor P-PTH decrease, the surgeon continued systematic neck exploration to identify the HPG(s).

Results from both imaging modalities were available to the surgeons to ensure the most optimal circumstances for positive surgical outcome. The best approach to surgery was discussed in multidisciplinary conferences and if the imaging results were discordant, surgeons would primarily follow the results from the Di-SPECT. However, it was always the surgeon's prerogative to remove suspect tissue.

Surgeons noted the number and weight of removed HPGs, their location relative to the thyroid gland, and concurrence with imaging results. All removed tissue was histologically classified by an experienced pathologist.

Postoperative follow-up was carried out after 2–3 weeks by the surgeons and after 1–3 months at the Department of Medicine, Division of Endocrinology, Herlev and Gentofte Hospital, Denmark, and included a clinical and biochemical evaluation.

2.4 | Statistical analysis

Location of the surgically removed tissue, confirmed by pathology as hyperfunctioning parathyroid tissue and normalisation of

postoperative biochemistry served as the reference standard. Only patients who were cured by PTx and for whom the true location of all potential HPGs was available to us were included in the statistical calculations.

At the patient level, sensitivities of Choline PET and Di-SPECT were calculated, where 'positive' was defined as a patient in whom one or more HPGs were found. As all patients were clinically diagnosed with PHPT and thus neither 'true negatives' nor 'false positives' should have existed, specificity was not relevant. At the gland level, however, calculation of both sensitivity and specificity was relevant because a single parathyroid gland could be either a true negative or true positive. We adjusted for clustered observations (i.e., multiple observations per patient) using a 'sandwich estimator' of variance with correlation adjusted confidence intervals (CIs).^{18,19} All statistical calculations were done using the statistical software R, version 4.0.2, June 2020 (R core Team (2020). R: A language and environment for statistical computing. R Foundation for Statistical Computing, Vienna, Austria. URL <https://www.R-project.org/>), and the following packages: *clubSandwich*, *clust.bin.pair*, *coninterper*, *PropCIs*, *readxl*, and *tableone*.

For simplicity, we assumed exactly four parathyroid glands per patient.

A confidence level of 95% was chosen, and all reported *p* values are exact. For further statistical details, please refer to our previous publication.¹³

3 | RESULTS

3.1 | Patient characteristics

A total of 100 patients met the inclusion criteria as defined in a previous publication¹³ and were included in the study. Patients were predominantly female (71%) with a median age of 62 years (range: 24–84 years). See Table 1 for baseline characteristics and Figure 3 for inclusion flow.

Seventeen patients with verified PHPT were screened for inclusion but did not meet inclusion criteria. Another 17 patients were excluded after inclusion. These 34 patients did not differ from the included patient population with regard to age, gender or preoperative P-Ca⁺⁺ or P-PTH.

Biochemistry (i.e., haematologic, hepatic and renal biomarkers) at inclusion was within normal range.

3.2 | Imaging and surgery

All patients underwent both imaging modalities. Reader certainty was high overall (75% and 76% in Choline PET and Di-SPECT, respectively). Surgery was performed 1–66 weeks after imaging. Pathology confirmed or refuted the presence of hyperfunctioning parathyroid tissue in the surgical specimens. Details on number of HPGs and certainty of imaging findings are shown in the Supporting Information (S1) and

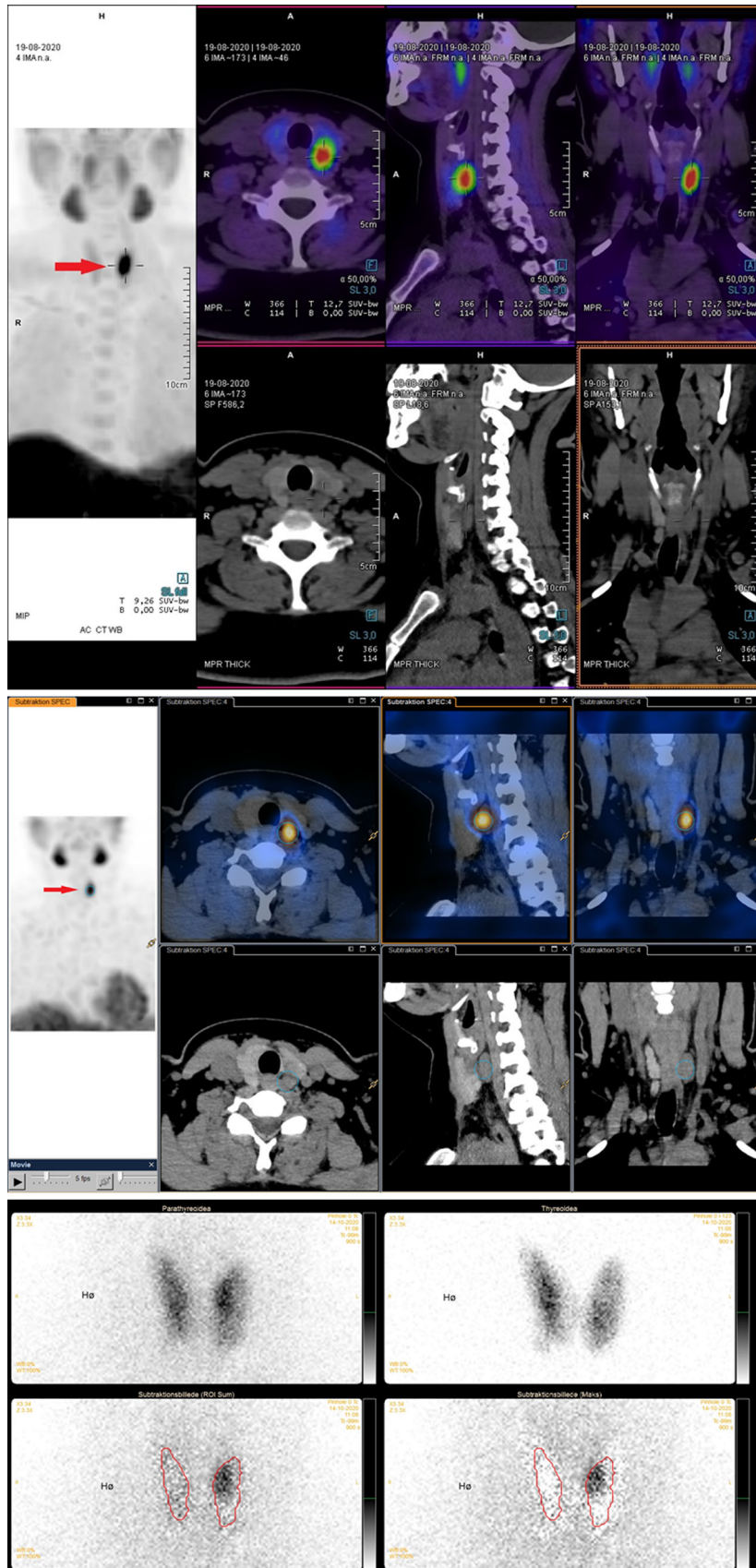
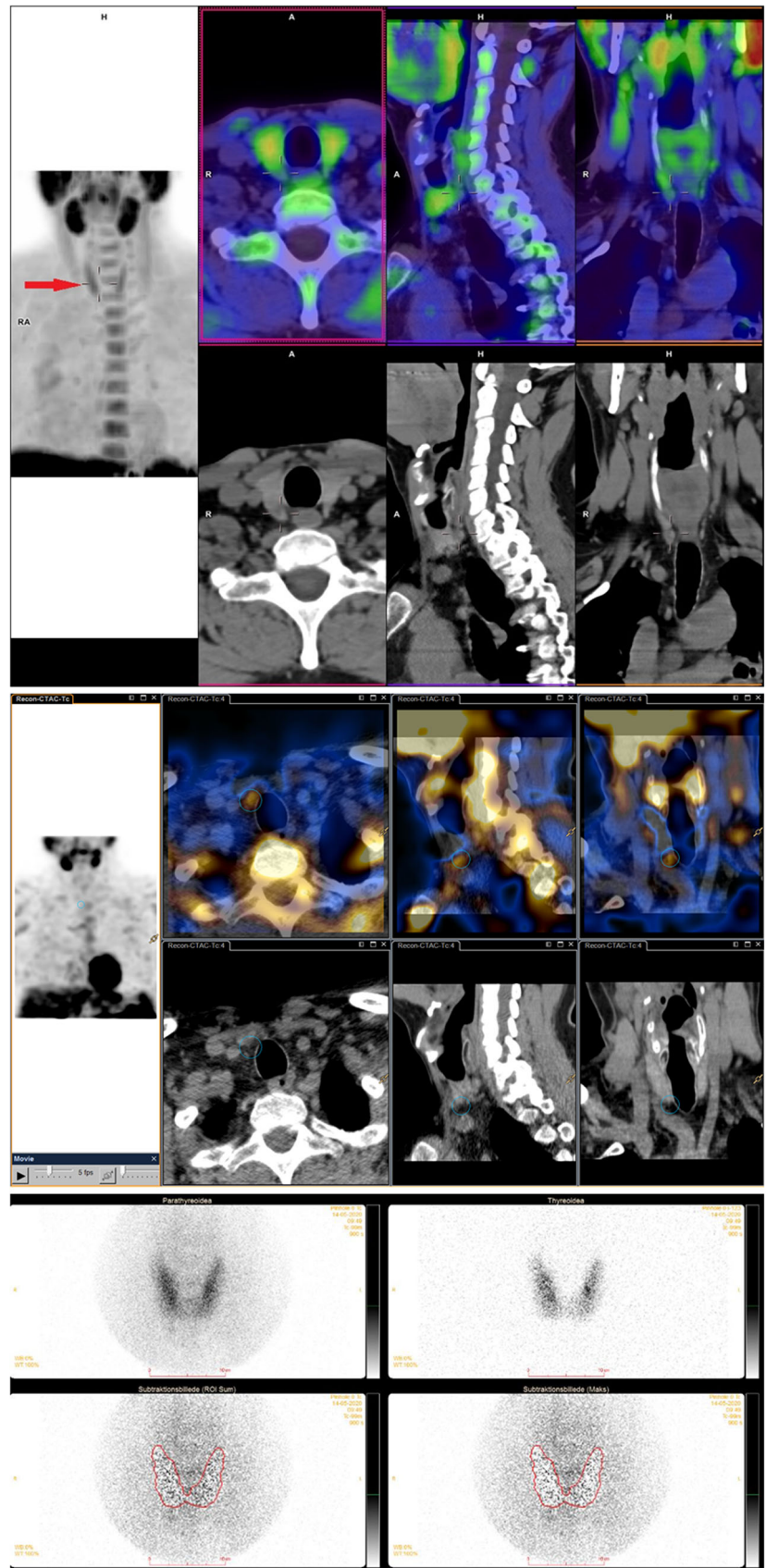


FIGURE 1 Images of a patient diagnosed with primary hyperparathyroidism. Parathyroid adenoma. Top ^{11}C -Choline PET/CT. Middle: Dual-isotope subtraction parathyroid scintigraphy with ^{99m}Tc -MIBI and ^{123}I iodide SPECT/CT. Bottom: Dual-isotope subtraction planar pinhole image. Arrows mark the suspected hyperfunctioning parathyroid gland in the upper left quadrant of the thyroid gland. The suspected HPG was surgically removed and pathology showed parathyroid adenoma [Color figure can be viewed at wileyonlinelibrary.com]

FIGURE 2 Images of a patient diagnosed with primary hyperparathyroidism. Parathyroid hyperplasia. Top¹¹C-Choline PET/CT. Middle: Dual-isotope subtraction parathyroid scintigraphy with ^{99m}Tc-MIBI and ¹²³Iodide SPECT/CT. Bottom: Dual-isotope subtraction planar pinhole image. Arrows mark the suspected hyperfunctioning parathyroid gland in the lower right quadrant of the thyroid gland. The suspected HPG was surgically removed and pathology showed parathyroid hyperplasia [Color figure can be viewed at wileyonlinelibrary.com]



surgical results, in S2. Of the 123 specimens removed during surgery, 23 (19%) contained no hyperfunctioning parathyroid tissue.

3.3 | Follow-up

The first postoperative follow-up was scheduled 1–6 months after surgery. At each follow-up, the endocrinologist evaluated the success of the surgery based on pathology (adenoma or hyperplasia),

normalized biochemistry and improvement of symptoms. One patient had below-normal P-PTH at first follow-up while P-PTH was above the lower limit after 6 months. Slight transient hypocalcaemia was found in one patient after 6 months ($p\text{-Ca}^{++} = 1.15 \text{ mmol/L}$), while slight hypocalcaemia occurred in five patients at the end of follow-up. All had $p\text{-Ca}^{++} = 1.16 \text{ mmol/L}$, which was deemed clinically inconsequential by the treating endocrinologist. Out of the 100 patients, 90 were cured by surgery.

Out of the 90 cured patients, 2 had ambiguous pathology (i.e., no certain hyperfunctioning parathyroid tissue removed) but normalized postoperative P- Ca^{++} indicating the true parathyroid was most likely removed during hemi-thyroidectomy but overlooked in pathology, or perhaps had the blood supply been severed eight surgical procedures were unsuccessful, and in two cases postoperative findings were inconclusive.

Postoperative follow-up ranged from 5 to 107 weeks. Most patients were followed for up to 1 year as outpatients. One patient died of illness not related to PHPT or surgery after only 5 weeks and another was transferred to follow-up at general practice after 9 weeks. In the remaining patients, follow-up was ≥ 6 months.

The maximal preoperative P- Ca^{++} and P-PTH values were registered and values monitored at each follow-up. The maximal rather than most recent preoperative measurements were chosen because these data were used for clinical decision-making in the presented cohort. The evolution of P- Ca^{++} and P-PTH is displayed in the Supporting Information (S3). Two patients had elevated P- Ca^{++} at the first follow-up. These later decreased to within-normal range. Some (10%) cured patients had P- Ca^{++} within normal range despite persistently elevated P-PTH.

Sensitivities and specificities are displayed in Table 2. Sensitivity at the gland level ($n = 400$ glands) was high: 87% (95% CI: 80%–93%) and 82% (95% CI: 73%–88%) for Di-SPECT and Choline PET, respectively. Exclusion of unsuccessful surgeries had little effect on results.

TABLE 1 Baseline patient characteristics

		N
Number of patients, <i>n</i>		100
Gender	Male	29
	Female	71
	Median	Range
Age at inclusion (years)	62	(24–84)
Height (cm)	171	(148–193)
Weight (kg)	79	(45–132)
BMI (kg/m^2)	26.6	(17.7–41.7)
Preoperative P-PTH (pmol/L)	17.1	(4.9–57.1)
Preoperative P- Ca^{++} (mmol/L)	1.49	(1.33–1.76)
Weeks between scans ^a	3	(0.1–16)
Weeks from final scan to surgery	18	(0.7–66)
Weeks of postoperative follow-up	51	(5–107)

Note: PTH: Parathyroid hormone, reference value: 2.0–8.5. Ca^{++} : Ionized Calcium, reference value: 1.18–1.32.

^aScans were performed on separate days. The order depended on availability and access to each scanner.

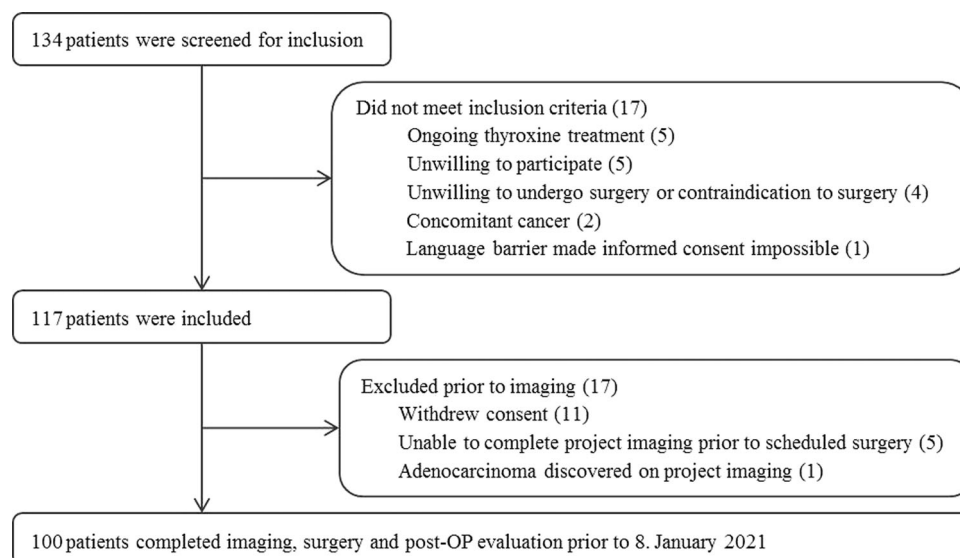


FIGURE 3 Inclusion flow from Department of Medicine, Division of Endocrinology, Herlev and Gentofte Hospital, Denmark

TABLE 2 Sensitivity and specificity of Choline PET and Di-SPECT (assuming four parathyroid glands per patient)

	N	Choline PET				Di-SPECT				p
		Sensitivity	(95% CI)	Specificity	(95% CI)	Sensitivity	(95% CI)	Specificity	(95% CI)	
All patients	400	81.6	(73.4–87.6)	92.9	(89.2–95.5)	87.4	(79.6–92.5)	94.3	(90.3–96.7)	.89
<i>Subgroup analysis</i>										
Cured patients only	360	82.0	(73.8–88.0)	94.6	(91.6–96.6)	87.0	(79.0–92.2)	95.8	(92.7–97.6)	.88
Nodular thyroid	44	88.9	(45.9–98.7)	94.3	(63.6–99.4)	88.9	(45.9–98.7)	88.6	(45.1–98.7)	.62
>1 HPGs	40	65.0	(49.0–78.2)	90	(82.3–94.6)	85.0	(63.7–94.8)	100	(100–100)	.72
Adenoma ^a	304	86.6	(77.8–92.2)	95.9	(92.8–97.8)	89.0	(80.4–94.1)	95.9	(92.3–97.9)	.84
Hyperplasia ^b	60	60.0	(41.4–76.1)	85.0	(72.7–92.3)	85.0	(63.5–94.9)	92.5	(79.1–97.6)	.81
Reader certainty low (Choline PET) ^c	72	64.7	(42.7–81.8)	78.2	(59.3–89.8)	76.5	(51.6–90.8)	92.7	(80.7–97.5)	.21
Reader certainty low (Di-SPECT) ^d	48	72.7	(42.9–90.4)	91.9	(76.1–97.6)	72.7	(42.9–90.4)	78.4	(50.5–92.8)	.27

^aSeventy-six patients had at least one pathologically confirmed parathyroid adenoma.

^bFifteen patients had at least one pathologically confirmed parathyroid hyperplasia.

^cEighteen patients had at least one HPG of low reader certainty on Choline PET scan.

^dTwelve patients had at least one HPG of low reader certainty on Di-SPECT scan.

A nodular thyroid as evaluated on ¹²³Iodine pinhole images was present in 11 cases, whereas 89 had a normal or slightly inhomogeneous uptake. Only seven (64%) of these were cured after surgery, so the condition is detrimental to surgical outcome. However, as our subsequent calculations are based upon cured patients only, sensitivity remains high for both modalities. This indicates that imaging is equally hampered by nodular thyroids as is surgery, but not more so.

Ten patients had more than one surgically confirmed HPG. Choline PET sensitivity in this subgroup appeared lower than in the total population at 65% (95% CI: 49%–78%), whereas Di-SPECT was unchanged at 85% (95% CI: 64%–95%). This difference was, however, not statistically significant ($p = .72$).

In 18 patients, one or more presumed HPG(s) had a low certainty score on Choline PET. The same was true in 12 patients when using Di-SPECT. Sensitivities were lower in patients where either reader was uncertain. There were no significant differences between modalities as p values remained above 0.2, but the group sizes were small.

Of the 100 included patients, 3 had previously undergone parathyroid surgery. In two cases, a single parathyroid adenoma was removed, and in the third no HPG was found despite neck exploration. The former two were cured by re-PTx, while the latter was not. During follow-up, no recurrence after previously deemed successful surgery was noted.

4 | DISCUSSION

The diagnostic performance of the two imaging modalities showed no statistically significant differences in terms of sensitivity or specificity. The diagnostic value of Choline PET/CT (¹⁸F or ¹¹C) compared to

conventional methods (primarily Di-SPECT or ^{99m}Tc-MIBI SPECT) has previously been found to be high with sensitivity above 87% and scintigraphy sensitivity slightly lower at 61%–81%.^{6,7,13,20–23} In patients where prior imaging (i.e., SPECT or ultrasound scanning) has been negative or inconclusive, Choline PET/CT (¹⁸F or ¹¹C) has demonstrated sensitivity up to 97% thus holding promise in this setting also.^{14,24–27}

In the total patient population, sensitivity at both the patient and gland level are equivalent. The two modalities found almost the same number of HPGs (PET Choline: 105 and Di-SPECT: 107 HPGs in total) and had the same number of high reader-certainty findings (75% and 76% of HPGs). The weight of HPGs (median 410 mg) is lower than in previous publications, for example, Krakauer et al.⁵ (median 665 mg) and Beheshti et al.²⁰ (median 1000 mg). This is likely due to earlier disease detection owing to increased use of P-Ca⁺⁺ measurements in routine diagnostic workup. The smaller HPG size might explain the slightly lower sensitivity of Choline PET in our study compared to the aforementioned studies.^{14,21} Others have reported a sensitivity of 98.8%, but as they included inconclusive HPG-foci as positive results, their cut-off was likely different from the present study.²⁴

In the subgroup analysis sensitivities are generally high, although Choline PET is slightly negatively affected by multiglandular disease as well as hyperplastic parathyroid glands. These results are, however, less certain due to smaller subgroups (10 and 15 patients, respectively). The apparent difference in patients with hyperplastic parathyroid glands is likely due to the lower contrast between HPGs and thyroid tissue on Choline PET images as compared to Di-SPECT images. Both thyroid tissue and HPGs exhibit choline uptake which can render the typically smaller hyperplastic parathyroid glands difficult to separate from thyroid tissue. A slightly longer interval from injection to image acquisition may allow for more washout from the thyroid gland,

which may in turn render HPGs more visible on Choline PET. The similar results found when analysing only patients with multiple HPGs is not surprising due to the overlap of these groups (50% of patients with multiple HPGs have at least one hyperplastic gland).

A hampering effect on imaging by nodular thyroids has been reported while others do not find this. A lower sensitivity in patients with hyperplasia than adenoma and among patients with multi gland disease than uniglandular disease has been reported for Di-SPECT, while Choline has not been investigated.^{29,30}

In patients with at least one HPG of 'low reader certainty' on Choline PET, decreased sensitivity is not surprising and the corresponding lower sensitivity on Di-SPECT demonstrates that HPGs in these patients are in fact more difficult to locate. Therefore, patients would not likely benefit from additional imaging using Di-SPECT before PTx.

While Choline PET and Di-SPECT appear widely interchangeable, sensitivity is not 100%. Therefore it is relevant to investigate if the modalities overlook the same HPGs or if they could supplement each other. We will address this in two parts: Preoperative (i.e., if no HPGs are located on first-line imaging, would additional preoperative second-line imaging be beneficial?) and Postoperative (i.e., if PTx is unsuccessful after first-line imaging, would additional second-line imaging be beneficial before repeat surgery?)

4.1 | Preoperative: If no HPGs are located on first-line imaging, would additional preoperative second-line imaging be beneficial?

In three and five cases, Choline PET and Di-SPECT found no HPG, respectively. In these cases, the alternative modality never identified all true HPGs, and only two of the seven ensuing PTx's were successful (Supporting Information, S4).

Imaging in these patients was challenged by a nodular thyroid in three patients (43%) and very small HPG(s) (median weight 195 mg). There were no differences between BMI, preoperative P-PTH or P-Ca⁺⁺ values when compared to the larger group.

It is thus unlikely that incremental information can be gained from the alternative modality if the first is negative. Furthermore, a negative scan of either kind should prompt thorough considerations about whether or not to perform PTx, choice of the surgeon's level of expertise, and managing patient expectations of surgical outcome.

4.2 | Postoperative: If PTx is unsuccessful after first-line imaging, would additional second-line imaging be beneficial before repeat surgery?

To address this, we evaluated all patients where either imaging modality was incorrect when compared to the reference standard (patients where imaging found nothing, found only one of two true HPGs or simply pointed to the wrong location; Table 3).

Choline PET was not completely correct in 19 cases; negative imaging in 3 cases, only one of two true HPGs identified in 6 cases and

TABLE 3 Correct and incorrect results of Choline PET and Di-SPECT

Choline PET incorrect (N = 19)	Cases	Of these Di-SPECT correct
Negative	3	0
Finds only one of two true HPGs	6	4
Incorrect location	10	6
Total	19	10
Di-SPECT incorrect (N = 15)	Cases	Of these Choline PET correct
Negative	5	0
Finds only one of two true HPGs	3	1
Incorrect location	7	6
Total	15	7

in 10 cases the reported location was wrong. Out of these 19 patients, Di-SPECT was correct in approximately half (10 of 19 cases).

Comparably, in 15 cases, Di-SPECT was not completely correct; negative imaging in 5 cases, only one of two true HPGs identified in 3 cases and in 7 cases the reported location was wrong. Again, of these 15 patients, Choline PET was correct in approx. half (7 of 15 cases).

In the patients where at least one of the two imaging modalities was incorrect or only partially correct, the HPGs were smaller (mean weight 327 mg) and the frequency of hyperplastic glands higher (40%) than in the overall group, potentially contributing to more difficult assessment. Gender and BMI were similar to the overall patient population. The clinical implication is that if PTx is unsuccessful and repeat surgery is considered, imaging with the alternate modality may provide useful information.

Though the method entails a short acquisition time (≈ 10 min) and a lower radiation dose (≈ 6.6 mSv), ¹¹C-Choline has a short half-life of only 20 min and therefore can only be performed in centres with an on-site cyclotron and radiochemistry facilities. A cyclotron is not imperative when using ¹⁸F Choline, due to its longer half-life (≈ 110 min),³¹ and ¹¹C Choline and ¹⁸F Choline is probably interchangeable in terms of sensitivity.^{6,7}

4.3 | Challenges

The project was conducted during the COVID-19 pandemic, and although this has not affected the quality of imaging, surgery, pathology or follow-up, it may have delayed diagnostic work-up and surgery.

5 | CONCLUSIONS

In this prospective, GCP-controlled cohort study we confirmed that overall Choline PET can contribute clinically useful information as accurately as Di-SPECT in preoperative localisation of HPGs in PHPT.

Results also indicated a high risk of futile surgery in patients with negative preoperative imaging, whether it be Choline PET or Di-SPECT. Negative preoperative imaging should prompt considerations regarding choice of surgical technique and level of experience of the surgeon. Also, little can be gained from additional preoperative imaging when one modality has been negative.

Regardless of modality, approximately half of patients with unsuccessful surgery after a positive finding on the first-line imaging modality would benefit from second-line imaging before repeating surgery.

Taking other benefits of Choline PET into account (i.e., radiation dose, time consumption, price and patient satisfaction) the overall results support introducing ^{11}C -Choline PET/CT as a prudent first-line modality for the preoperative localisation of HPGs.

ACKNOWLEDGMENTS

Special thanks to Associate Professor Katalin Kiss for her involvement in the pathological classification and review. The authors wish to thank the referring endocrinologists and the teams at the PET unit and scintigraphy unit at Herlev and Gentofte Hospital. J.W.C. received partial funding from the Scientific Committee of Herlev University Hospital.

CONFLICT OF INTERESTS

The authors declare no conflict of interest.

DATA AVAILABILITY STATEMENT

The data that support the findings of this study are available from the corresponding author upon reasonable request.

ORCID

Julie W. Christensen  <http://orcid.org/0000-0003-2680-0121>

Susanne B. Søndergaard  <http://orcid.org/0000-0002-3390-5637>

Finn N. Bennedbak  <http://orcid.org/0000-0002-2301-2878>

Birte Nygaard  <http://orcid.org/0000-0002-9540-4950>

Lars T. Jensen  <http://orcid.org/0000-0003-1846-4498>

Martin Krakauer  <http://orcid.org/0000-0002-2191-1861>

REFERENCES

- Fraser WD. Hyperparathyroidism. *Lancet*. 2009;374:145-158. doi:10.1016/S0140-6736(09)60507-9
- Greenspan BS, Dillehay G, Intenzo C, et al. SNM practice guideline for parathyroid scintigraphy 4.0. *J Nucl Med Technol*. 2012;40:111-118. doi:10.2967/jnmt.112.105122
- Rejnmark L. Danish Endocrine Society – Treatment guideline for Primary hyperparathyroidism. [website]. October 2018. Accessed September 10, 2021. <https://endocrinology.dk/nbv/calcium-og-knoglemetabolisme/primaer-hyperparathyreoidisme/>
- Syed H, Khan A. Primary hyperparathyroidism: diagnosis and management in 2017. *Polish Arch Intern Med*. 2017;127:438-441. doi:10.20452/pamw.4029
- Krakauer M, Wieslander B, Myschetzky PS, et al. A prospective comparative study of parathyroid dual-phase scintigraphy, dual-isotope subtraction scintigraphy, 4D-CT, and ultrasonography in primary hyperparathyroidism. *Clin Nucl Med*. 2016;41:93-100. doi:10.1097/RLU.0000000000000988
- Ferrari C, Santo G, Mammucci P, Pisani AR, Sardaro A, Rubini G. Diagnostic value of choline PET in the preoperative localization of hyperfunctioning parathyroid gland(s): a comprehensive overview. *Biomedicines*. 2021;9:231. doi:10.3390/biomedicines9030231
- Evangelista L, Ravelli I, Magnani F, et al. 18F-choline PET/CT and PET/MRI in primary and recurrent hyperparathyroidism: a systematic review of the literature. *Ann Nucl Med*. 2020;34:601-619. doi:10.1007/s12149-020-01507-1
- Christensen JW, Krakauer M. Added value of subtraction SPECT/CT in dual-isotope parathyroid scintigraphy. *Diagnostics*. 2020;10:639. doi:10.3390/diagnostics10090639
- Rink T, Schroth HJ, Holle LH, Garth H. Limited sensitivity of parathyroid imaging with 99mTc-sestamibi/123I subtraction in an endemic goiter area. *J Nucl Med*. 2002;43:1175-1180.
- Hassler S, Ben-Sellem D, Hubele F, Constantinesco A, Goetz C. Dual-isotope 99mTc-MIBI/123I parathyroid scintigraphy in primary hyperparathyroidism: comparison of subtraction SPECT/CT and pinhole planar scan. *Clin Nucl Med*. 2014;39:32-36. doi:10.1097/RLU.0000000000000272
- Mapelli P, Busnardo E, Magnani P, et al. Incidental finding of parathyroid adenoma with 11C-choline PET/CT. *Clin Nucl Med*. 2012;37:593-595. doi:10.1097/RLU.0b013e31824c5ffc
- Orevi M, Freedman N, Mishani E, Bocher M, Jacobson O, Krausz Y. Localization of parathyroid adenoma by 11C-choline PET/CT: preliminary results. *Clin Nucl Med*. 2014;39:1033-1038. doi:10.1097/RLU.0000000000000607
- Ismail A, Christensen JW, Krakauer M, et al. 11C-choline PET/CT vs. 99m Tc-MIBI/123 Iodine subtraction SPECT/CT for preoperative detection of abnormal parathyroid glands in primary hyperparathyroidism: a prospective, single-centre clinical trial in 60 patients. *Diagnostics*. 2020;10:1-10. doi:10.3390/diagnostics10110975
- Noltes ME, Kruijff S, Jansen L, et al. A retrospective analysis of the diagnostic performance of 11C-choline PET/CT for detection of hyperfunctioning parathyroid glands after prior negative or discordant imaging in primary hyperparathyroidism. *EJNMMI Res*. 2021;11:11. doi:10.1186/s13550-021-00778-7
- Korwar V, Yuen Chang F, Teasdale E, Suchett-Kaye I, Edwards A, Morgan J. Stepwise approach for parathyroid localisation in primary hyperparathyroidism. *World J Surg*. 2020;44:803-809. doi:10.1007/s00268-019-05269-4
- Sun L, Yao J, Hao P, Yang Y, Liu Z, Peng R. Diagnostic role of four-dimensional computed tomography for preoperative parathyroid localization in patients with primary hyperparathyroidism: a systematic review and meta-analysis. *Diagnostics*. 2021;11:11. doi:10.3390/diagnostics11040664
- Wan QC, Li JF, Tang LL, et al. Comparing the diagnostic accuracy of 4D CT and 99mTc-MIBI SPECT/CT for localizing hyperfunctioning parathyroid glands: a systematic review and meta-analysis. *Nucl Med Commun*. 2021;42:225-233. doi:10.1097/MNM.0000000000001331
- Genders TSS, Spronk S, Stijnen T, Steyerberg EW, Lesaffre E, Hunink MGM. Methods for calculating sensitivity and specificity of clustered data: a tutorial. *Radiology*. 2012;265:910-916. doi:10.1148/radiol.12120509
- Obuchowski NA. On the comparison of correlated proportions for clustered data. *Stat Med*. 1998;17:1495-1507. doi:10.1002/(SICI)1097-0258(19980715)17:13<1495::AID-SIM863>3.0.CO;2-I
- Beheshti M, Hehenwarter L, Paymani Z, et al. 18F-fluorocholine PET/CT in the assessment of primary hyperparathyroidism compared with 99mTc-MIBI or 99mTc-tetrofosmin SPECT/CT: a prospective dual-centre study in 100 patients. *Eur J Nucl Med Mol Imaging*. 2018;45:1762-1771. doi:10.1007/s00259-018-3980-9
- Cuderman A, Senica K, Rep S, et al. 18F-fluorocholine PET/CT in primary hyperparathyroidism: superior diagnostic performance to conventional scintigraphic imaging for localization of hyperfunctioning

- parathyroid glands. *J Nucl Med*. 2020;61:577-583. doi:10.2967/jnumed.119.229914
22. Araz M, Soydal Ç, Özkan E, et al. The efficacy of fluorine-18-choline PET/CT in comparison with 99mTc-MIBI SPECT/CT in the localization of a hyperfunctioning parathyroid gland in primary hyperparathyroidism. *Nucl Med Commun*. 2018;39:989-994. doi:10.1097/MNM.0000000000000899
 23. Giovannella L, Bacigalupo L, Treglia G, Piccardo A. Will 18F-fluorocholine PET/CT replace other methods of preoperative parathyroid imaging? *Endocrine*. 2021;71:285-297. doi:10.1007/s12020-020-02487-y
 24. Liu Y, Dang Y, Huo L, et al. Preoperative localization of adenomas in primary hyperparathyroidism: the value of 11C-choline PET/CT in patients with negative or discordant findings on ultrasonography and 99mTc-sestamibi SPECT/CT. *J Nucl Med*. 2020;61:584-589. doi:10.2967/jnumed.119.233213
 25. Quak E, Blanchard D, Houdou B, et al. F18-choline PET/CT guided surgery in primary hyperparathyroidism when ultrasound and MIBI SPECT/CT are negative or inconclusive: the APACH1 study. *Eur J Nucl Med Mol Imaging*. 2018;45:658-666.
 26. Morland D, Lalire P, Deguelte S, et al. Added value of 18F-fluorocholine positron emission tomography-computed tomography in presurgical localization of hyperfunctioning parathyroid glands after dual tracer subtraction scintigraphy failure: a retrospective study of 47 patients. *Medicine*. 2020;99:99. doi:10.1097/MD.00000000000018681
 27. Pretet V, Rotania M, Helali M, Ignat M, Vix M, Imperiale A. 18F-fluorocholine pet and multiphase CT integrated in dual modality PET/4D-CT for preoperative evaluation of primary hyperparathyroidism. *J Clin Med*. 2020;9:1-12. doi:10.3390/JCM9062005
 28. Erbil Y, Barbaros U, Yanik BT, et al. Impact of gland morphology and concomitant thyroid nodules on preoperative localization of parathyroid adenomas. *The Laryngoscope*. 2006;116(4):580-585. <https://doi.org/10.1097/01.mlg.0000203411.53666.ad>
 29. Zhu M, He Y, Liu T, et al. Factors that affect the sensitivity of imaging modalities in primary hyperparathyroidism. *Int J Endocrinol*. 2021;2021:1-8. <https://doi.org/10.1155/2021/3108395>
 30. Wakamatsu H, Noguchi S, Yamashita H, et al. Parathyroid scintigraphy with 99mTc-MIBI and 123I subtraction: a comparison with magnetic resonance imaging and ultrasonography. *Nucl Med Commun*. 2003;24(7):755-762. <https://doi.org/10.1097/00006231-200307000-00004>
 31. Chondrogiannis S, Marzola MC, Grassetto G, et al. New acquisition protocol of 18F-choline PET/CT in prostate cancer patients: Review of the literature about methodology and proposal of standardization. *Biomed Res Int*. 2014;2014:1-10. <https://doi.org/10.1155/2014/215650>

SUPPORTING INFORMATION

Additional supporting information may be found in the online version of the article at the publisher's website.

How to cite this article: Christensen JW, Ismail A, Søndergaard SB, et al. Preoperative imaging in primary hyperparathyroidism: Are ¹¹C-Choline PET/CT and ^{99m}Tc-MIBI/¹²³Iodide subtraction SPECT/CT interchangeable or do they supplement each other? *Clinical Endocrinology*. 2022;1-10. doi:10.1111/cen.14688